

## Endoscopic endonasal transsphenoidal surgery for growth hormone–secreting pituitary adenomas

CHRISTOPH P. HOFSTETTER, M.D., Ph.D.,<sup>1</sup> RAAID H. MANNA, M.D.,<sup>5</sup> LYNN MUBITA, M.D.,<sup>1</sup> VIJAY K. ANAND, M.D.,<sup>2</sup> JOHN W. KENNEDY, M.D.,<sup>5</sup> AMIR R. DEHDASHTI, M.D.,<sup>4,6</sup> AND THEODORE H. SCHWARTZ, M.D.<sup>1-3</sup>

Departments of <sup>1</sup>Neurological Surgery, <sup>2</sup>Otolaryngology, and <sup>3</sup>Neurology and Neuroscience, Weill Cornell Medical College, New York–Presbyterian Hospital, New York, New York; Departments of <sup>4</sup>Neurological Surgery and <sup>5</sup>Endocrinology, Geisinger Clinic, Danville; and <sup>6</sup>Department of Neurosurgery, Temple University School of Medicine, Philadelphia, Pennsylvania

**Object.** The aim of this study was to determine the preoperative predictors of the extent of resection and endocrinological remission following endonasal endoscopic removal of growth hormone (GH)-secreting pituitary adenomas.

**Methods.** The authors analyzed a prospectively collected database of 24 consecutive acromegalic patients who underwent endoscopic endonasal transsphenoidal surgery. The extent of resection was evaluated on postoperative contrast-enhanced MR imaging. Endocrinological remission was defined as normal insulin-like growth factor I (IGF-I) serum levels and either a nadir GH level of < 0.4 ng/ml after an oral glucose load or a basal GH serum level < 1 ng/ml.

**Results.** The majority of acromegalic patients (83%) had macroadenomas > 1 cm in maximum diameter. Gross-total resection was achieved in 17 (71%) of 24 patients. Notably, endoscopic transsphenoidal surgery allowed complete resection of all lesions without cavernous sinus invasion, regardless of the suprasellar extent. Biochemical remission was achieved in 11 (46%) of 24 patients. A smaller tumor volume and a postoperative reduction in GH serum levels were associated with a higher rate of biochemical cure ( $p < 0.05$ ). During a 23-month follow-up period 5 patients (21%) underwent Gamma Knife treatment of any residual disease to further reduce excess GH production. Twenty patients (83%) reported significant relief of their symptoms, while 3 (13%) considered their symptoms stable. Two patients (8%) with large macroadenomas experienced postoperative panhypopituitarism, and 2 patients (8%) suffered from CSF leaks, which were treated with lumbar CSF diversion.

**Conclusions.** A purely endoscopic endonasal transsphenoidal adenoma resection leads to a high rate of gross-total tumor resection and endocrinological remission in acromegalic patients, even those harboring macroadenomas with wide suprasellar extension. Extended approaches and angled endoscopes are useful tools for increasing the extent of resection. (DOI: 10.3171/2010.7.FOCUS10173)

**KEY WORDS** • endoscopy • acromegaly • growth hormone • insulin-like growth factor I • minimally invasive procedure • transsphenoidal surgery • skull base

**A**CROMEGALY is most commonly caused by GH-secreting pituitary adenomas. This rare but very serious condition carries at least twice the mortality rate compared with that in the general population.<sup>3,26,28,34</sup> Excessive secretion of GH causes cardiovascular disease, musculoskeletal deformity, diabetes mellitus, and an increased incidence of malignancies. Cardiovascular and cerebrovascular accidents are common causes of death in acromegalic patients. Importantly, the normalization of GH levels alleviates symptoms and reduces mortality

*Abbreviations used in this paper:* GH = growth hormone; GKS = Gamma Knife surgery; GTR = gross-total resection; IGF-I = insulin-like growth factor I; STR = subtotal resection.

rates to those in the general population. Thus, a definition of cured acromegaly involves the normalization of excessive GH secretion as determined by circulating IGF-I and nadir GH of < 0.4 ng/ml after an oral glucose load.<sup>12,13,23</sup> Although somatostatin analogs and the GH receptor antagonist pegvisomant are increasingly prescribed as adjunct or even primary therapy, resection remains the first-line treatment. In patients with intrasellar microadenomas, microsurgical removal alone provides biochemical control with the normalization of IGF-I in 75%–95% of patients; control rates decrease to 40%–68% of patients with macroadenomas.<sup>21,25,33</sup> Resection can be performed either alone or in combination with the administration of medical treatment as well as radiotherapy.<sup>22</sup>

In the current study we describe our experience with a purely endoscopic endonasal transsphenoidal approach in 24 patients with GH-secreting pituitary adenomas. Our aim was to analyze predictors of biochemical and clinical outcomes after the endoscopic resection of such lesions.

## Methods

### *Patient Demographics*

We reviewed a prospectively collected database of all endoscopic endonasal surgeries for GH-secreting pituitary adenomas performed at Weill Cornell Medical College, New York–Presbyterian Hospital, Geisinger Neurosciences Institute, and Temple University School of Medicine between February 2004 and May 2010 as a collaboration between the Departments of Neurosurgery and Otolaryngology. Patients selected for this study all underwent surgery during which an endoscopic endonasal transsphenoidal approach was used. In 3 patients an extended transsphenoidal approach with removal of the tuberculum sellae and planum sphenoidal was performed.<sup>18</sup> All patients underwent preoperative MR imaging. All tumors were analyzed using contrast-enhanced MR images on postoperative Day 1, at 3 months after surgery, and then at a yearly interval. Tumor volume was approximated by an ellipsoid model by using the product of the maximal anteroposterior, lateral, and rostrocaudal radii.<sup>2,17,36</sup> Invasion of the cavernous sinus was diagnosed according to the following criteria: three-fourths or more encasement of the internal carotid artery, obliteration of the carotid sulcus venous compartment, or crossing of the lateral intercarotid line by the tumor.<sup>6</sup> For each surgery, the pathology, duration of surgery, estimated blood loss, type of exposure, use of intraoperative fluorescein and lumbar drainage, technique of closure, and complications were recorded. The institutional review board at both institutions approved the study.

### *Surgical Technique*

Following the induction of general anesthesia, antibiotics, glucocorticoids, and intrathecal fluorescein are given.<sup>27</sup> BrainLAB neuronavigation is routinely used. A detailed description of the procedure has already been published.<sup>18,31</sup> Briefly, after topical exposure of the nasal mucosa to cocaine and injection of the mucosa of the middle turbinates with a mixture of lidocaine 1% and epinephrine (1:100,000), the sphenoid ostia are bilaterally identified and the bony opening is enlarged. The posterior third of the nasal septum adjacent to the vomeric bone and maxillary crest is resected with a tissue shaver. The anterior wall of the sella is opened using a high-speed drill and curettes. In more recent cases with large macroadenomas, a nasoseptal flap may be harvested at the start of the case. For the resection of microadenomas, an attempt is made to remove the tumor en bloc. For macroadenomas, the lesion is first internally decompressed by removing the inferior portion of the tumor followed by the lateral portions to prevent the suprasellar arachnoid from herniating down into the sella and obstructing the view. The suprasellar component is resected last. Exposure of this region may require an extended approach

including removal of the tuberculum sellae and planum sphenoidale. Tumor is dissected off the medial wall of the cavernous sinus. Angled endoscopes are used to enter the cavernous sinus and remove tumor that can easily be dissected from this area. Closure is performed in a multilayer fashion.<sup>20</sup>

### *Endocrinological Evaluation*

Basal fasting levels of GH and IGF-I were measured in the serum of patients preoperatively, postoperatively, and at the time of the last follow-up. Biochemical remission was evaluated according to IGF-I serum levels combined with an oral glucose tolerance test in 10 patients. A glucose tolerance test was considered normal if serum GH levels were suppressed to < 0.4 ng/ml following a 75-g oral glucose load. In the remaining 14 patients, biochemical remission was evaluated by IGF-I levels combined with basal GH levels. Random basal GH serum levels of  $\leq 1$  ng/ml were considered normal. Insulin-like growth factor I was always evaluated according to age-related diagrams. Our goal is to attempt an oral glucose test to determine cure in all patients, but this test is not always possible in patients referred from outside endocrinologists who may not comply or follow up reliably at our institution.

### *Statistical Evaluation*

Continuous variables are displayed as the means  $\pm$  SD and the range. Categorical values are shown as percentages. Associations between the effect of tumor size, invasion of the cavernous sinus, extension into the suprasellar cistern, or preoperative GH serum levels on endocrinological remission and the extent of resection were calculated using a chi-square test for categorical variables and the Pearson correlation coefficient for continuous variables. Postoperative GH serum levels were compared using a Mann-Whitney U-test. Outcome predictors were determined with binary logistic regression modeling. A *p* value < 0.05 was considered significant.

## Results

### *Patient Characteristics*

Twenty-four patients who underwent purely endoscopic transsphenoidal resection of GH-secreting pituitary adenomas were included in the series. The cohort consisted of 13 males and 11 females with a mean age of  $50.7 \pm 14.7$  years (range 22–75 years; Table 1). Approximately half of these patients presented with increases in ring and shoe size as well as the typical coarse acromegalic facial features. Fewer patients sought medical attention for bone and joint pain or amenorrhea. The majority of lesions were macroadenomas defined by a maximum diameter > 1 cm. However, presenting symptoms were attributable to excess hormonal production in all but 1 patient, who presented with diplopia caused by tumor invasion of the cavernous sinus. None of the patients demonstrated impairment on preoperative visual field testing. Assessment of preoperative contrast-enhanced MR imaging revealed a cavernous sinus invaded by tumor in 10 patients.

# Endoscopic resection of GH-secreting pituitary adenomas

**TABLE 1: Summary of characteristics in 24 patients with acromegaly\***

Characteristic	No. (%)
sex	
M	13 (54.2)
F	11 (45.8)
mean age (yrs)	50.7 ± 14.7
previous op	
yes	4 (16.7)
no	20 (83.3)
presenting symptoms	
increased ring & shoe size	11 (45.8)
bone & joint pain	4 (16.7)
amenorrhea	2 (8.4)
max tumor diameter	
microadenoma (<1 cm)	4 (16.7)
macroadenoma (>1 cm)	19 (83.3)
invasion of the CS	
yes	10 (41.7)
no	14 (58.3)
suprasellar tumor extension	
yes	7 (29.2)
no	17 (70.8)
GTR	
yes	17 (70.8)
no	7 (29.2)
mean FU (mos)	23.2 ± 25.4

\* CS = cavernous sinus; FU = follow-up.

The tumor extended into the suprasellar cistern in 7 patients. The average duration of the follow-up period from resection to laboratory testing was 23 months (range 1–74 months).

## Surgical Results

Purely endoscopic transsphenoidal surgeries lasted an average of 182 minutes (range 104–326 minutes). The estimated blood loss was 153 ml (range 30–800 ml). An extended transsphenoidal approach was performed in 3 patients with suprasellar tumor expansion and invasion of the cavernous sinus. In more than two-thirds of the cases, intrathecal fluorescein was given to label the CSF, which is an institutional protocol at Weill Cornell Medical College. Intraoperative CSF leaks were encountered in approximately one-half of the patients (Table 2). In 83% of the cases with intraoperative CSF leaks, abdominal fat was harvested for the enforcement of a multilayer closure. Twenty-five percent of these patients also underwent spinal CSF drainage for 3 days to facilitate watertight closure of the skull base defect. Postoperative MR imaging revealed that GTR was achieved in 71% of the cases. Two factors were associated with STR; greater tumor volume and cavernous sinus invasion were linked to a higher rate of residual tumor ( $p < 0.01$  and  $p < 0.001$ , respectively; Fig.

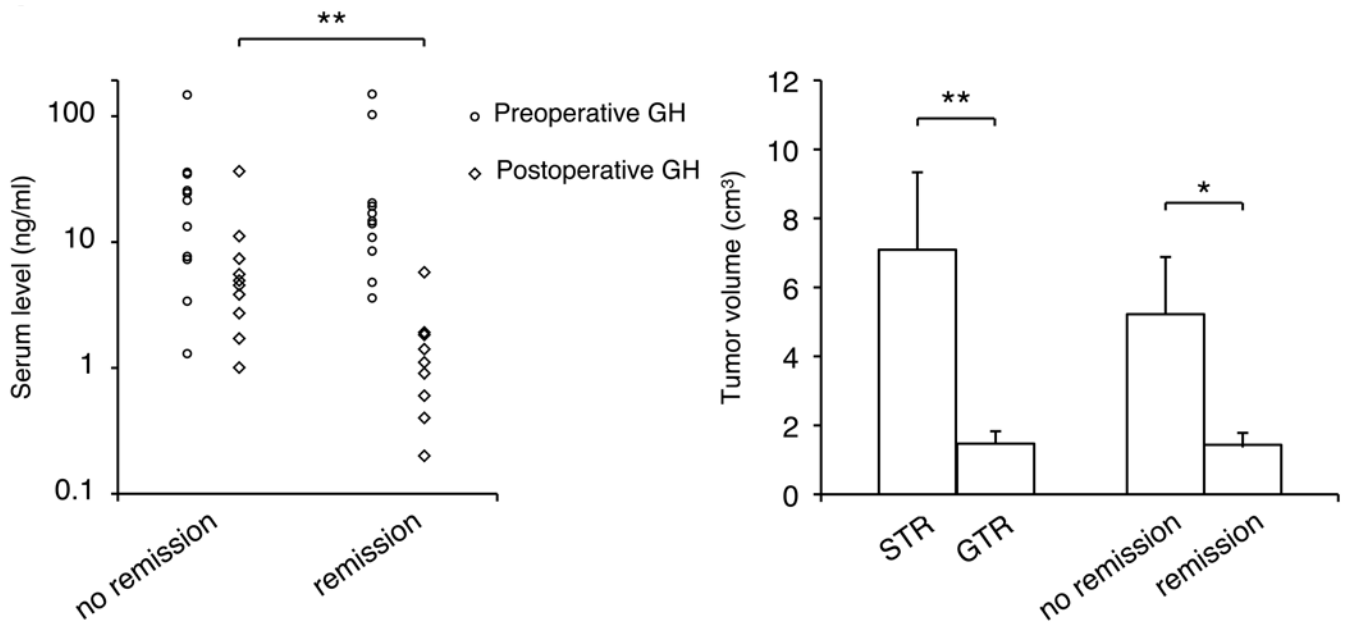
**TABLE 2: Summary of operative details in 24 patients with acromegaly**

Parameter	No. (%)
mean op time (min)	181.6 ± 57.3
mean estimated blood loss (ml)	153.1 ± 206.4
extended approach	
yes	3 (12.5)
no	21 (87.5)
intrathecal fluorescein	
yes	18 (75.0)
no	6 (25.0)
intraop CSF leak	
yes	13 (54.2)
no	11 (45.8)
closure of skull base defect	
fat	13 (54.2)
vomer	10 (41.6)
fascia lata	2 (8.3)
DuraSeal	24 (100.0)
lumbar drain	
yes	3 (12.5)
no	21 (87.5)
mean hospital stay (days)	3.6 ± 1.8

1). Gross-total tumor resection was achieved in all patients who did not have invasion of the cavernous sinus and in 3 of the 10 patients who did have cavernous sinus invasion. Thus, residual tumor was identified in the cavernous sinus of 7 patients. In 1 of these patients residual tumor was also found in the frontal lobe, and in another patient tumor was left in the suprasellar cistern. Note, however, that tumor expansion into the suprasellar cistern was not correlated with a higher rate of STR. Only tumor volume was a significant predictor for GTR, according to a logistic regression model ( $p < 0.05$ ). Five patients who underwent STR and had poor control of their GH serum levels underwent GKS. One of these patients achieved biochemical remission following adjuvant medical therapy. Another 2 patients had near complete restoration of GH and IGF-I levels and did not require medical treatment. However, 2 of these 5 patients who underwent GKS continued to have poor control of excess GH secretion despite adjuvant medical therapy.

## Endocrinological Outcome

Preoperative serum GH levels of 31 ng/ml (range 1–150 ng/ml) decreased to 4 ng/ml (range 0–36 ng/ml) postoperatively. Insulin-like growth factor I levels of 806 ng/ml prior to surgery (range 15–1321 ng/ml) decreased to 462 ng/ml (range 6–937 ng/ml) postoperatively (Table 3). At 23 months after resection, 11 patients (46%) had a biochemical cure. Considering only patients with macroadenomas (maximum diameter > 1 cm), the rate of endocrinological remission decreased to 42%. A smaller tumor volume was associated with a higher rate of biochemical cure by endoscopic transsphenoidal surgery ( $p$



**Fig. 1.** Graphs showing the association between GH levels or tumor size and endocrinological remission. Comparison of pre- and postoperative GH serum levels in patients with and without endocrinological remission (**left**). Horizontal line indicates the median. Lesions associated with GTR and endocrinological remission are significantly smaller than lesions for which no GTR or remission was achieved (**right**). Values are shown as the means. Error bars represent the SEM. \* $p < 0.05$  and \*\* $p < 0.01$ .

$< 0.05$ ; Fig. 1). While preoperative GH serum levels did not differ significantly between patients who demonstrated an endocrinological remission and those who did not, postoperative GH serum levels were significantly lower in patients who had a remission ( $p < 0.01$ ). Thus, postoperative GH serum level was a significant predictor of endocrinological remission in a logistic regression model ( $p < 0.05$ ). Of 11 patients in biochemical remission, 9 were cured by resection alone. One patient achieved endocrinological remission by a combination of resection, GKS, and adjuvant medical therapy, and 1 patient by resection and adjuvant medical therapy (Table 3). Seven of the 13 patients who did not achieve endocrinological remission required medical therapy for elevated GH serum levels. The other 6 patients had GH levels close to normal so that their endocrinologist selected conservative treatment with serial GH and IGF-I serum level checks.

#### Clinical Outcome and Complications

Twenty-three months after resection, 25% of the patients believed that their initial presenting symptoms had normalized and another 58% experienced significant improvement in their condition (Table 4). The remaining patients felt no change in their symptoms, and 1 patient with severe bone and joint pain believed that he had gotten worse following surgery.

Two patients who had an intact hypothalamic-pituitary axis prior to the procedure demonstrated panhypopituitarism following resection of their adenoma. Notably, the lesions in both of these cases were macroadenomas. Cerebrospinal fluid rhinorrhea developed in 2 patients after the resection of a GH-secreting macroadenoma. Both CSF leaks were successfully treated with 3–4 days of lumbar CSF drainage. Two patients suffered from sinusitis

following the procedure and were treated with oral antibiotics. Transient diplopia was noticed by a patient who underwent resection of a recurrent pituitary macroadenoma with invasion of the cavernous sinus. Immediately after the procedure the patient demonstrated cranial nerve VI paresis ipsilateral to the side of invasion.

#### Discussion

Resection is currently the first-line treatment for GH-secreting adenomas. While endocrinological remission leads to symptom relief and the restoration of normal life expectancy, some patients are not cured by surgical treatment alone. Analysis of the determinants of a failed endoscopic transsphenoidal technique may assist in appropriate patient selection and further refinement of the procedure.

During the last few decades, the criteria for endocrinological remission have been constantly revised.<sup>12,13</sup> In early series, GH levels  $< 5$  ng/ml were used to define biochemical remission.<sup>1,29</sup> Using these criteria, Abosch et al.<sup>1</sup> report that 76% of 254 patients had endocrinological remission after transsphenoidal pituitary resection. Similarly, Ross and Wilson<sup>29</sup> found GH levels  $< 5$  ng/ml in 79% of 165 patients at the 76-month follow-up. However, basal GH levels are an unreliable marker for endocrinological remission given the pulsatile nature of GH secretion and the changes in serum levels with sleep, age, and nutritional status of a patient.<sup>14</sup> For that reason, subsequent studies included an assessment of the absolute nadir in levels of GH after an oral glucose load. Using a nadir level  $< 2$  ng/ml, Fahlbusch et al.<sup>8</sup> reported a 57% rate of endocrinological remission after transsphenoidal surgery. More recent studies have used stricter criteria such as a

# Endoscopic resection of GH-secreting pituitary adenomas

**TABLE 3: Treatment characteristics and endocrinological outcome of 24 patients with GH-secreting pituitary adenomas\***

Case No.	Age (yrs) & Sex	Preop GH	Preop IGF-I	Postop GH	Postop IGF-I	GKS	Adjuvant Medical Therapy	Last FU GH	Last FU IGF-I	OGTT†	Endocrin Cure	FU (mos)
1	48, F	13.3	624	4.5	261	yes	none	1.7	274	NA	no	10
2	56, M	NA	15.4	3.8	6.4	yes	none	4.8	267	NA	no	47
3	55, M	7.7	NA	1.0	422	no	none	NA	NA	NA	no	44
4	37, F	NA	773	5.7	506	yes	bromocriptine, cabergoline, Sandostatin	0.9	180	NA	yes	61
5	48, M	4.8	940	0.2	530	no	none	0.1	118	NA	yes	74
6	35, F	1.3	411	1.7	288	no	none	1.7	120	NA	no	13
7	60, M	35.9	567	2.7	313	no	none	2.7	313	NA	no	53
8	58, M	103	757	0.9	190	no	none	0.9	165	NA	yes	66
9	65, M	8.5	902	1.1	635	no	none	0.8	191	normal	yes	21
10	66, F	10.9	534	1.4	85	no	none	0.017	87	NA	yes	24
11	65, F	3.6	836	0.4	547	no	none	0.056	148	NA	yes	31
12	39, M	19.3	855	0.2	597	no	none	0.1	135	NA	yes	4
13	69, M	24.6	895	4.9	478	no	Sandostatin	2.2	200	NA	no	69
14	65, F	14.7	1012	1.8	526	no	cabergoline	0.98	260	normal	yes	6
15	60, M	16.9	NA	1.9	539	no	none	1.9	289	abnormal	no	5
16	44, M	7.3	1251	1.0	602	yes	octreotide	0.3	394	normal	no	4
17	26, F	148	1022	11	841	yes	octreotide	3.4	655	abnormal	no	5
18	22, F	25.7	660	36	756	no	octreotide	18	884	NA	no	1
19	56, F	150	626	0.4	87	no	none	0.7	145	NA	yes	1
20	58, M	20.5	896	0.6	407	no	none	7.0	198	normal	yes	3
21	40, M	34.8	1297	7.3	937	no	Sandostatin	3.1	290	abnormal	no	2
22	75, M	14	1241	1.1	494	no	none	0.9	140	normal	yes	5
23	26, F	21.5	1321	2.7	900	no	Sandostatin	3.9	799	abnormal	no	3
24	44, F	3.4	296	5.5	147	no	Sandostatin	3.4	193	abnormal	no	4
average		31.4	806.0	4.1	462.0			2.7	286.8			23.2
SD		43.4	330.0	7.3	255.5			3.9	216.6			25.4

\* All serum hormone levels are expressed in ng/ml. Abbreviations: Endocrin = Endocrinological; NA = not applicable; OGTT = oral glucose tolerance test.

† Test is considered normal if serum GH is lower than 0.4 ng/ml following a 75-g oral glucose load.

nadir level < 1 ng/ml.<sup>3,19,25</sup> But a nadir level < 1 ng/ml would miss the diagnosis of acromegaly in up to 25% of patients.<sup>7,11</sup> Given the widespread availability of ultrasensitive GH assays, a recent consensus statement proposed a nadir level < 0.4 ng/ml as the criterion for an endocrinological cure.<sup>13</sup> An additional criterion for endocrinological cure also includes an assessment of IGF-I serum levels, which reflects integrated 24-hour GH secretion and remains relatively constant over the day. Normalization of IGF-I levels has been demonstrated following the successful treatment of acromegaly.<sup>5,15,30</sup> Consequently, normal IGF-I levels and a nadir level < 1 ng/ml of GH after a glucose load were proposed by a consensus statement in 2000 as criteria for an acromegaly cure.<sup>12</sup> The application of these criteria yielded endocrinological remission rates of 57%–67% after microsurgical transsphenoidal approaches.<sup>3,19,25</sup> When considering only pituitary macroadenomas (diameter > 1 cm), Nomikos et al.<sup>25</sup> reported an

endocrinological remission in 51% of patients, and Beau-regard et al.<sup>3</sup> documented remission in 47%. Using more stringent criteria for endocrinological remission as proposed by a consensus statement from 2010,<sup>13</sup> we report a 46% endocrinological remission rate in our patients with GH-secreting pituitary adenomas.

In the current series a purely endoscopic transsphenoidal technique was used. In accordance with microscopic transsphenoidal series, we found that tumor volume was a predictor of resectability and an endocrinological cure.<sup>3,25</sup> Using a purely endoscopic technique, we found residual suprasellar tumor in only 1 of 7 patients with suprasellar tumor extension. In contrast, tumor was left in 7 of 10 patients with invasion of the cavernous sinus. This finding contrasts with that in a study by Bohinski and colleagues,<sup>4</sup> who investigated the extent of macroadenoma resection via a microsurgical technique by using intraoperative MR imaging. In that series, residual tumor was

**TABLE 4: Clinical outcomes and complications in 24 patients with acromegaly**

Parameter	No. (%)
adjuvant medical treatment	
yes	9 (37.5)
no	15 (62.5)
GKS	
yes	5 (20.8)
no	19 (79.2)
endocrinological remission	
yes	11 (54.2)
no	13 (45.8)
clinical outcome	
asymptomatic	6 (25.0)
improved	14 (58.3)
stable	3 (12.5)
worse	1 (4.2)
complication	
panhypopituitarism	2 (8.4)
CSF leak	2 (8.4)
sinusitis	2 (8.4)
diplopia	1 (4.2)

detected both in the suprasellar cistern and adjacent to the cavernous sinus in 66% of all cases. A similar rate of residual tumor was reported by Nimsy and colleagues.<sup>24</sup> In their series, intraoperative MR imaging detected residual disease in 41.5% of all macroadenomas treated with a microsurgical transsphenoidal technique. The superiority of the endoscopic technique for visualizing the pathology in the suprasellar cistern was very recently demonstrated by Theodosopoulos et al.,<sup>35</sup> who performed intraoperative MR imaging after purely endoscopic transsphenoidal tumor resections. In a series of 27 patients, these authors were able to detect tumor remnants in the suprasellar cistern in 2 of 5 cases utilizing the endoscopic technique. These results are similar to those of Schwartz et al.,<sup>32</sup> who found residual tumor with intraoperative MR imaging in only 20% of patients after endoscopic surgery. The endoscopic technique offers the advantage of a wider field of view, better illumination, and the possibility of looking around corners using angled scopes. The ability to visualize and resect lesions in the suprasellar cistern was corroborated in the current series. However, tumor invasion of the cavernous sinus remains associated with a high rate of STR and poor disease control. Nevertheless, more aggressive surgery within the cavernous sinus by using endoscopic techniques has been shown to lead to a higher rate of endocrinological cure.<sup>9,10,16</sup>

While the current series demonstrates a high rate of endocrinological remission after endoscopic macroadenoma resection, additional larger studies using the most recent criteria for endocrinological cure are needed to corroborate our findings. Larger studies may also allow for subgroup analysis with regard to various tumor sizes and grades. Our results may be skewed by the adjuvant

radiation and/or medical therapy that more than one-third of our patients received, but this limitation is inherent to the retrospective nature of our study. Mounting a controlled study of the separate use of resection, radiation, or medical therapy would be barely feasible.

## Conclusions

In summary, an endoscopic transsphenoidal approach for the resection of GH-secreting pituitary adenomas leads to endocrinological remission in 46% of patients. Procedure-associated morbidity is low and three-fourths of our patients experienced improvement of their clinical symptoms. While the endoscopic technique greatly facilitates the resectability of lesions in the suprasellar cistern, resection of a tumor in the cavernous sinus remains a challenge.

## Disclosure

Dr. Kennedy is a principal investigator for Lilly and Novo Nordisk Diabetes Clinical Trials. The authors report no other conflict of interest concerning the materials or methods used in this study or the findings specified in this paper.

Author contributions to the study and manuscript preparation include the following. Conception and design: Schwartz, Hofstetter, Dehdashti. Acquisition of data: all authors. Analysis and interpretation of data: Hofstetter, Dehdashti. Drafting the article: Hofstetter, Mannaa, Mubita. Critically revising the article: Schwartz, Anand, Dehdashti. Reviewed final version of the manuscript and approved it for submission: Schwartz, Anand, Dehdashti. Statistical analysis: Hofstetter. Study supervision: Schwartz.

## References

- Abosch A, Tyrrell JB, Lamborn KR, Hannegan LT, Applebury CB, Wilson CB: Transsphenoidal microsurgery for growth hormone-secreting pituitary adenomas: initial outcome and long-term results. *J Clin Endocrinol Metab* **83**:3411–3418, 1998
- Alahmadi H, Vachhrajani S, Cusimano MD: The natural history of brain contusion: an analysis of radiological and clinical progression. Clinical article. *J Neurosurg* **112**:1139–1145, 2010
- Beauregard C, Truong U, Hardy J, Serri O: Long-term outcome and mortality after transsphenoidal adenomectomy for acromegaly. *Clin Endocrinol (Oxf)* **58**:86–91, 2003
- Bohinski RJ, Warnick RE, Gaskill-Shipley MF, Zuccarello M, van Loveren HR, Kormos DW, et al: Intraoperative magnetic resonance imaging to determine the extent of resection of pituitary macroadenomas during transsphenoidal microsurgery. *Neurosurgery* **49**:1133–1144, 2001
- Clemmons DR, Van Wyk JJ, Ridgway EC, Kliman B, Kjellberg RN, Underwood LE: Evaluation of acromegaly by radioimmunoassay of somatomedin-C. *N Engl J Med* **301**:1138–1142, 1979
- Cottier JP, Destrieux C, Brunereau L, Bertrand P, Moreau L, Jan M, et al: Cavernous sinus invasion by pituitary adenoma: MR imaging. *Radiology* **215**:463–469, 2000
- Dimaraki EV, Jaffe CA, DeMott-Friberg R, Chandler WF, Barkan AL: Acromegaly with apparently normal GH secretion: implications for diagnosis and follow-up. *J Clin Endocrinol Metab* **87**:3537–3542, 2002
- Fahlbusch R, Honegger J, Buchfelder M: Surgical management of acromegaly. *Endocrinol Metab Clin North Am* **21**:669–692, 1992
- Frank G, Pasquini E: Endoscopic endonasal approaches to the cavernous sinus: surgical approaches. *Neurosurgery* **50**:675, 2002

## Endoscopic resection of GH-secreting pituitary adenomas

10. Frank G, Pasquini E: Endoscopic endonasal cavernous sinus surgery, with special reference to pituitary adenomas. **Front Horm Res** **34**:64–82, 2006
11. Freda PU, Reyes CM, Nuruzzaman AT, Sundeen RE, Bruce JN: Basal and glucose-suppressed GH levels less than 1 microg/L in newly diagnosed acromegaly. **Pituitary** **6**:175–180, 2003
12. Giustina A, Barkan A, Casanueva FF, Cavagnini F, Frohman L, Ho K, et al: Criteria for cure of acromegaly: a consensus statement. **J Clin Endocrinol Metab** **85**:526–529, 2000
13. Giustina A, Chanson P, Bronstein MD, Klibanski A, Lamberts S, Casanueva FF, et al: A consensus on criteria for cure of acromegaly. **J Clin Endocrinol Metab** **95**:3141–3148, 2010
14. Ho KY, Veldhuis JD, Johnson ML, Furlanetto R, Evans WS, Alberti KG, et al: Fasting enhances growth hormone secretion and amplifies the complex rhythms of growth hormone secretion in man. **J Clin Invest** **81**:968–975, 1988
15. Kao PC, Laws ER Jr, Zimmerman D: Somatomedin C/insulin-like growth factor I levels after treatment of acromegaly. **Ann Clin Lab Sci** **22**:95–99, 1992
16. Kitano M, Taneda M, Shimono T, Nakao Y: Extended transsphenoidal approach for surgical management of pituitary adenomas invading the cavernous sinus. **J Neurosurg** **108**:26–36, 2008
17. Kothari RU, Brott T, Broderick JP, Barsan WG, Sauerbeck LR, Zuccarello M, et al: The ABCs of measuring intracerebral hemorrhage volumes. **Stroke** **27**:1304–1305, 1996
18. Laufer I, Anand VK, Schwartz TH: Endoscopic, endonasal extended transsphenoidal, transplanum transtuberulum approach for resection of suprasellar lesions. **J Neurosurg** **106**:400–406, 2007
19. Laws ER, Vance ML, Thapar K: Pituitary surgery for the management of acromegaly. **Horm Res** **53** (Suppl 3):71–75, 2000
20. Leng LZ, Brown S, Anand VK, Schwartz TH: “Gasket-seal” watertight closure in minimal-access endoscopic cranial base surgery. **Neurosurgery** **62** (5 Suppl 2):ONSE342–ONSE343, 2008
21. Ludecke DK, Abe T: Transsphenoidal microsurgery for newly diagnosed acromegaly: a personal view after more than 1,000 operations. **Neuroendocrinology** **83**:230–239, 2006
22. Melmed S, Casanueva F, Cavagnini F, Chanson P, Frohman LA, Gaillard R, et al: Consensus statement: medical management of acromegaly. **Eur J Endocrinol** **153**:737–740, 2005
23. Melmed S, Colao A, Barkan A, Molitch M, Grossman AB, Kleinberg D, et al: Guidelines for acromegaly management: an update. **J Clin Endocrinol Metab** **94**:1509–1517, 2009
24. Nimsky C, von Keller B, Ganslandt O, Fahlbusch R: Intraoperative high-field magnetic resonance imaging in transsphenoidal surgery of hormonally inactive pituitary macroadenomas. **Neurosurgery** **59**:105–114, 2006
25. Nomikos P, Buchfelder M, Fahlbusch R: The outcome of surgery in 668 patients with acromegaly using current criteria of biochemical ‘cure.’ **Eur J Endocrinol** **152**:379–387, 2005
26. Orme SM, McNally RJ, Cartwright RA, Belchetz PE: Mortality and cancer incidence in acromegaly: a retrospective cohort study. **J Clin Endocrinol Metab** **83**:2730–2734, 1998
27. Placantonakis DG, Tabae A, Anand VK, Hiltzik D, Schwartz TH: Safety of low-dose intrathecal fluorescein in endoscopic cranial base surgery. **Neurosurgery** **61** (3 Suppl):161–166, 2007
28. Rajasoorya C, Holdaway IM, Wrightson P, Scott DJ, Ibbertson HK: Determinants of clinical outcome and survival in acromegaly. **Clin Endocrinol (Oxf)** **41**:95–102, 1994
29. Ross DA, Wilson CB: Results of transsphenoidal microsurgery for growth hormone-secreting pituitary adenoma in a series of 214 patients. **J Neurosurg** **68**:854–867, 1988
30. Schatz H, Stracke H, Zapf J: [Diagnosis in acromegaly. Insulin-like growth factor as a parameter of activity.] **Dtsch Med Wochenschr** **108**:1391–1395, 1983 (Ger)
31. Schwartz TH, Anand VK: The endoscopic endonasal transsphenoidal approach to the suprasellar cistern. **Clin Neurosurg** **54**:226–235, 2007
32. Schwartz TH, Stieg PE, Anand VK: Endoscopic transsphenoidal pituitary surgery with intraoperative magnetic resonance imaging. **Neurosurgery** **58** (1 Suppl):ONS44–ONS51, 2006
33. Shimon I, Cohen ZR, Ram Z, Hadani M: Transsphenoidal surgery for acromegaly: endocrinological follow-up of 98 patients. **Neurosurgery** **48**:1239–1245, 2001
34. Swearingen B, Barker FG II, Katznelson L, Biller BM, Grinspoon S, Klibanski A, et al: Long-term mortality after transsphenoidal surgery and adjunctive therapy for acromegaly. **J Clin Endocrinol Metab** **83**:3419–3426, 1998
35. Theodosopoulos PV, Leach J, Kerr RG, Zimmer LA, Denny AM, Guthikonda B, et al: Maximizing the extent of tumor resection during transsphenoidal surgery for pituitary macroadenomas: can endoscopy replace intraoperative magnetic resonance imaging? Clinical article. **J Neurosurg** **112**:736–743, 2010
36. Wapnir IL, Wartenberg DE, Greco RS: Three dimensional staging of breast cancer. **Breast Cancer Res Treat** **41**:15–19, 1996

Manuscript submitted June 21, 2010.

Accepted July 23, 2010.

Address correspondence to: Theodore H. Schwartz, M.D., Department of Neurological Surgery, Weill Cornell Medical College, New York–Presbyterian Hospital, 525 East 68th Street, Box 99, New York, New York 10021. email: schwarh@med.cornell.edu.