Neurosurgical Focus

Surgical indications in patients with an intracerebral hemorrhage due to a ruptured middle cerebral artery aneurysm

Masami Shimoda, M.D., Shinri Oda, M.D., Yoshiaki Mamata, M.D., Ryuichi Tsugane, M.D., and Osamu Sato, M.D.

Department of Neurosurgery, Tokai University School of Medicine, Kanagawa, Japan

The authors retrospectively analyzed surgical outcomes in patients with an intracerebral hemorrhage (ICH) due to a ruptured middle cerebral artery aneurysm. A total of 47 patients with ICH who underwent early aneurysm surgery and hematoma evacuation within 24 hours following onset were studied. The types of ICH were classified into three groups by computerized tomography findings: 1) temporal ICH; 2) intrasylvian hematoma; and 3) ICH with diffuse subarachnoid hemorrhage (SAH). Overall, 25 patients (54%) had a favorable outcome and 18 (38%) died. Prognostic factors that predicted a favorable outcome included age less than 60 years, temporal ICH, World Federation of Neurological Surgeons Grade II or III, absence of a surgical complication, and a hematoma volume of less than 25 ml. In the patients with temporal ICH, eight of nine patients had a good recovery, and no patient developed a surgical complication or a delayed ischemic deficit. The most important predictive factor for a favorable outcome in patients with an intrasylvian hematoma was that they underwent early surgery (within 6 hours after symptom onset). In patients with a temporal ICH or intrasylvian hematoma, the initial neurological examination did not accurately predict outcome. By contrast, in the patients with ICH and diffuse SAH, those who developed an ICH with a volume of 25 ml or greater had a poor prognosis. These results suggest that aggressive surgical treatment should be initiated in patients with a temporal ICH or an intrasylvian hematoma, regardless of neurological findings on admission. In patients with an ICH and diffuse SAH, careful review of surgical indications is required.

Key Words * subarachnoid hemorrhage * intracerebral hemorrhage * middle cerebral artery aneurysm * cerebral angiogram

Many investigators agree that patients with a massive intracerebral hemorrhage (ICH) due to a ruptured middle cerebral artery (MCA) aneurysm should undergo immediate surgery to relieve increased intracranial pressure.[2-5,7,9,10,12,13,18,20] In our experience with these patients, however, individual surgical results were variable, and outcomes were not as good as expected. Although in our patient series, patients recovered fully despite fatal neurological findings at their initial presentation, similar to postoperative patients with an acute epidural hematoma. Accordingly, this retrospective study reinvestigated surgical indications for patients with an ICH due to a ruptured MCA aneurysm.

CLINICAL MATERIAL AND METHODS

Patient Population

Unauthenticated | Downloaded 04/26/23 11:42 AM UTC

Six hundred five patients with nontraumatic SAH were admitted to Tokai University Hospital from January 1985 to December 1994. Of these patients, there were 116 with an ICH due to a primary aneurysm rupture and 63 of these were due to a ruptured MCA aneurysm. Forty-seven of the 63 patients in the MCA group underwent obliteration of the aneurysm neck and evacuation of the ICH within 24 hours following SAH. Exclusion criteria for patients receiving surgical intervention were as follows: 1) age greater than 76 years (five cases); 2) absent intracranial filling on angiography after contrast media administration (one case); 3) absent brainstem signs such as light, oculocephalia, and corneal reflexes (although patients whose reflexes returned to normal promptly following rapid injection of mannitol did subsequently undergo surgical intervention (six cases)); 4) hypotension and/or apnea on admission due to brainstem impairment (one case); and 5) admission at the subacute or chronic stage (five cases).

A diagnosis of SAH with ICH was based on clinical findings and computerized tomography (CT) evidence of subarachnoid clots and intraparenchymal hemorrhage (more than 10 ml). Preoperative angiography was not performed in two patients because of their critical condition and the need for emergency craniotomy. Ultimately, a ruptured MCA aneurysm was demonstrated by preoperative angiography and all patients underwent surgery.

Diagnostic Tools

Classifications and Scales. The clinical grade of each patient was determined on admission according to the system of the World Federation of Neurological Surgeons (WFNS).[6] Using the Glasgow Outcome Scale,[8] the outcome for each patient was classified as either good recovery and moderate disability (a favorable outcome) or as poor recovery with severe disability, a vegetative state, or death (an unfavorable outcome).

The types of ICH were classified into three groups according to CT findings (Fig. 1) on admission: 1) temporal ICH (with or without a minor SAH); 2) intrasylvian hematoma (with or without a minor SAH); and 3) ICH with a diffuse SAH (SAH with cisternal clots on the side contralateral to the ICH).

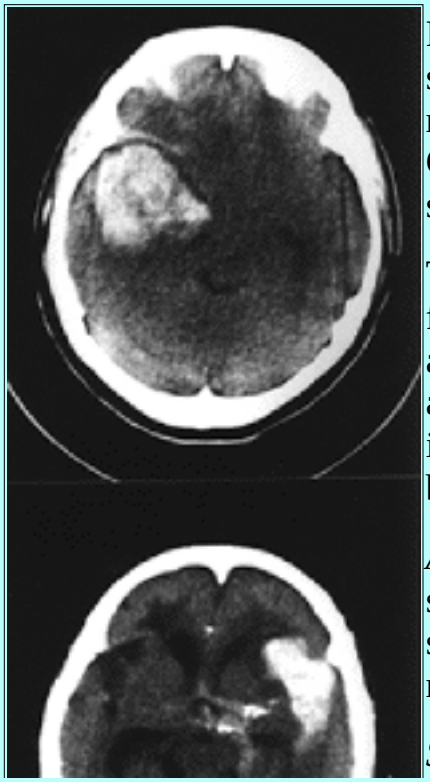

Fig. 1. Representative preoperative computerized tomography scanning demonstrating an intracerebral hemorrhage (ICH) due to a ruptured middle cerebral artery aneurysm. Upper: Temporal ICH, Center: Intrasylvian hematoma, and Lower: ICH with diffuse subarachnoid hemorrhage.

The diagnosis of a delayed ischemic deficit was made by assessing the findings on serial angiography, the development of a focal neurological abnormality following recovery from the immediate postoperative state, and a CT scan without evidence of hydrocephalus. Complications from surgical intervention such as contusions and edema in the brain parenchyma caused by retraction during surgery were also considered.

Angiographic Evaluations. The patients' cerebral angiograms were studied specifically to assess any elevation of the sphenoid segment of the MCA and sylvian point, the distance between the insula and internal table (normal range 20-30 mm), and the midline shift on the anteroposterior projection.

Surgical Procedure. A pterional craniotomy, wider than the ordinary

Unauthenticated | Downloaded 04/26/23 11:42 AM UTC

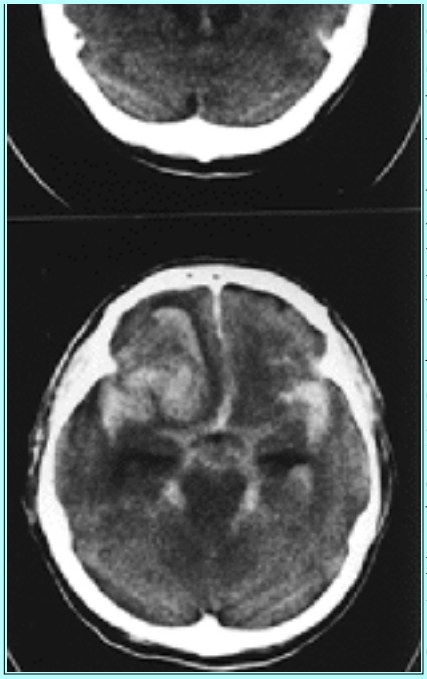

approach used for aneurysms, was performed. After the dura had been opened, the clot was partially removed distal to the aneurysm to provide brain relaxation. A temporal lobectomy was performed when severe brain bulging was present. Obliteration of the MCA aneurysm was achieved via a transsylvian approach using standard microsurgical technique, and the hematoma was evacuated completely after clipping. If cerebral swelling persisted, a duraplasty was performed, and the bone flap was not replaced.

Postoperative Management. An immediate postoperative CT scan was obtained in all patients and compared with their preoperative studies. If findings indicative of brain herniation were still present on the CT scan and/or the neurological examination, the patient was given a course of barbiturate medications to induce a burst-suppression coma. All patients received osmotherapy, a continuous infusion of nicardipine (2-10 µg/kg/minute) or diltiazem (2-15 µg/kg/minute). If a patient developed a delayed ischemic deficit, optimum hypervolemic therapy, consistent with that of our previously performed therapeutic regimen, was administered concomitant with continuous infusion of dobutamine with or without dopamine.[16,17] In the most recent cases, no hypervolemic therapy was administered in the patients with massive brain edema due to a primary aneurysmal ICH or to vasospasm, but instead osmotherapy, with or without a barbiturate regimen, was given.

Statistical Analysis

Multiple logistic regression analysis was used to identify the independent factors prediciting prognosis. The other data from patients were compared using the Pearson chi-square or t-test. All statistical analyses were performed using commercially available software (SPSS, Version 6.1.3; Marija J. Norusis/SPSS, Inc., Chicago, IL).

RESULTS

Clinical Features and Outcome

Overall, 25 patients (54%) had a favorable outcome (good recovery in 20 cases, moderate disability in five cases), three (6%) suffered from severe disability, one (2%) remained in a vegetative state, and 18 (38%) died.

The mean age was significantly younger in patients with favorable outcomes than in patients with unfavorable outcomes. Based on the WFNS grading system, 10 patients were categorized as Grade II, five as Grade III, 20 as Grade IV, and 12 as Grade V. Patients with favorable outcomes were more likely to have received an initial grade of II or higher than patients with unfavorable outcomes. Abnormal findings on preoperative neurological examination, such as aniscoria, absence of light reflex, and negative oculocephalic reflex, did not significantly differ between patient groups (Table 1).

Unauthenticated | Downloaded 04/26/23 11:42 AM UTC

TABLE 1

RELATIONSHIP BETWEEN CLINICAL FEATURES AND OUTCOMES IN PATIENTS UNDERGOING EARLY SURGERY FOR INTRACEREBRAL HEMORRHAGE (ICH) DUE TO A RUPTURED MIDDLE CEREBRAL ARTERY ANEURYSM*

Variable	Favorable Outcome	Unfavorable Outcome	Total
no. of cases	25	22	47
mean age†	49 ± 12	59 ± 13	53 ± 13
WFNS grade on admission			
II‡	7	1	8
III	3	2	5
IV	9	12	21
V	6	7	13
anisocoria (NS)			
yes	5	7	12
no	20	15	35
light reflex (NS)			
prompt	24	18	42
absent	1	4	5
oculocephalic reflex (NS)			
positive	25	20	45
negative	0	2	2
hematoma type			
temporal ICH‡	8	1	9
intrasylvian hematoma†	11	5	16
ICH with diffuse SAH	6	16	22
mean hematoma volume (ml)†	26 ± 17	42 ± 24	33 ± 22
angiographic midline shift (mm)†	4 ± 5	7 ± 6	5 ± 5
early surgery within 6 hrs of onset (NS)			
yes	10	13	23
no	15	9	24
surgical complication‡			
no	21	9	30
yes	4	13	17
delayed ischemic deficit (NS)			
no	18	11	29
yes	7	11	18
rerupture (NS)			
no	23	18	41
yes	2	4	6

*NS = not significant; SAH = subarachnoid hemorrhage; WFNS = World Federation of Neurological Surgeons.
† Significance was determined according to the chi-square test or t-test ($p < 0.05$).
‡ $p < 0.01$.

Patients with favorable outcomes were more likely to have a temporal ICH or intrasylvian hematoma revealed on initial CT scanning. Patients with unfavorable outcomes had a higher mean hematoma volume and greater midline shift on angiography than patients with favorable outcomes. Early surgery (within 6 hours of symptom onset), a delayed ischemic deficit, and rerupture did not significantly differ between patient groups. Surgical complications (postoperative hemorrhage in four cases and contused brain due to retraction in 13 cases) were significantly higher in patients with unfavorable outcomes (Table 1).

Clinical Features and Hematoma Type

The relationship between clinical features and hematoma type is summarized in Table 2. The mean age, mean hematoma volume, and WFNS grade on admission in the three groups did not differ significantly. There was no incidence of a delayed ischemic deficit in the patients with temporal ICH. Furthermore, no patient with a temporal ICH had a surgical complication. In the patients with ICH and diffuse SAH, the

Unauthenticated | Downloaded 04/26/23 11:42 AM UTC

incidence of surgical complications was 59% (13 of 22 cases: 10 patients had contused brain damage due to retraction and three patients developed postoperative hemorrhage). This complication rate was significantly higher than in the other two hematoma groups. The incidence of surgical complications in the patients with an intrasylvian hematoma was 25% (four patients had brain injury due to retraction).

TABLE 2
RELATIONSHIP BETWEEN CLINICAL FEATURES AND HEMATOMA TYPE*

Variable	Temporal ICH	Intrasylvian Hematoma	ICH With SAH
no. of cases	9	16	22
mean age	52 ± 11	49 ± 15	57 ± 12
mean hematoma volume (ml)	39 ± 24	26 ± 21	36 ± 21
WFNS grade on admission			
II	2	3	3
III	1	3	1
IV	3	6	12
V	3	4	6
delayed ischemic deficit			
yes	0	6†	12†
no	9	10	10
surgical complication			
yes	0	4	13‡
no	9	12	9
Glasgow Outcome Scale			
good recovery	8–8 ‡	9–11 †	3–6
moderate disability	0	2	3
severe disability	0	1	2
vegetative state	0	0	1
death	1	4	13

* Abbreviations: ICH = intracerebral hemorrhage; SAH = subarachnoid hemorrhage; WFNS = World Federation of Neurological Surgeons. Significance was determined according to the chi-square test or t-test.
† = $p < 0.05$.
‡ = $p < 0.01$.

The percentage of favorable outcomes was higher in patients with a temporal ICH (eight (89%) of nine cases) and intrasylvian hematoma (11 (69%) of 16 cases) than in patients with ICH and diffuse SAH (six (27%) of 22 cases). In the patients with temporal ICH, eight of nine patients had a good recovery; the only patient death was due to cardiac failure.

Hematoma Volume and Outcome

Patients with ICH and diffuse SAH who had a hematoma with a volume greater than 25 ml also had significantly worse outcomes. The outcome of patients with a temporal ICH or an intrasylvian hematoma did not correlate with hematoma volume (Table 3).

Unauthenticated | Downloaded 04/26/23 11:42 AM UTC

TABLE 3
RELATIONSHIP BETWEEN HEMATOMA VOLUME AND PROGNOSIS*

	Hematoma Volume			
	Favorable Outcome		Unfavorable Outcome	
Hematoma Type	< 25 ml	> 25 ml	< 25 ml	> 25 ml
temporal ICH	2	6	0	1
intrasylvian hematoma	6	5	2	3
ICH with diffuse SAH	5	1	1	15†
total	13	12	3	19†

* ICH = intracerebral hemorrhage; SAH= subarachnoid hemorrhage.
† Significance was determined according to the chi-square test: $p < 0.01$.

Prognostic Factors in Two Hematoma Types

We examined the correlation between clinical features and prognosis in patients with an intrasylvian hematoma or an ICH with diffuse SAH (Table 4). In the patients with an intrasylvian hematoma, early surgery (within 6 hours after onset) resulted in a favorable outcome (Table 4). In patients with ICH and diffuse SAH, an ICH volume of 25 ml or less correlated with a favorable outcome (Tables 3 and 4).

TABLE 4
CLINICAL FEATURES AND OUTCOME IN PATIENTS WITH AN INTRASYLVIAN HEMATOMA AND PATIENTS WITH INTRACEREBRAL HEMORRHAGE (ICH) AND DIFFUSE SUBARACHNOID HEMORRHAGE*

Variable	Favorable Outcome	Unfavorable Outcome	Total
no. of cases	11(6)	5(16)	16(22)
mean age	46 ± 13	56 ± 18	49 ± 15
	(54 ± 14)	(59 ± 11)	(57 ± 12)
WFNS grade on admission			
II	3(2)	0(1)	3(3)
III	2(0)	1(1)	3(1)
IV	3(3)	3(9)	6(12)
V	3(1)	1(5)	4(6)
anisocoria	3(1)	1(5)	4(6)
absent light reflex	0(0)	1(1)	1(1)
negative oculocephalic reflex	0(0)	1(2)	1(2)
mean hematoma volume (ml)	24 ± 17	29 ± 32	26 ± 21
	(21 ± 15)	(43 ± 20)†	(36 ± 21)
midline shift (mm)	5 ± 7	5 ± 6	5 ± 6
	(3 ± 3)	(8 ± 6)	(6 ± 5)
early surgery within 6 hrs after onset	10(3)†	2(9)	12(12)
surgical complication	1(2)	2(9)	3(11)
delayed ischemic deficit	5(3)	2(10)	7(13)
rerupture	3(2)	1(1)	4(3)

* Abbreviation: WFNS = World Federation of Neurological Surgeons. Significance was determined according to the chi-square test or t-test: † = $p < 0.05$. Parentheses indicate that the data pertains to the patients with ICH and diffuse subarachnoid hemorrhage.

Angiographic Diagnosis of Hematoma Type

Findings in each hematoma type, such as elevation of the M1 segment, elevation of the sylvian point, distance between the inner table and insular segment, and midline shift, are summarized in Table 5. Patients with a temporal ICH were more likely to have elevation of the M1 segment and an increased distance between the inner table and insular segment as compared to patients with other types of hematomas (Table 5).

Unauthenticated | Downloaded 04/26/23 11:42 AM UTC

TABLE 5
RELATIONSHIP BETWEEN ANGIOGRAPHIC FINDINGS AND HEMATOMA TYPE

Factor	Temporal ICH	Intrasylvian Hematoma*	ICH With SAH*
M1 elevation			
yes	7‡	3	4
no	2	12	17
elevation of sylvian point			
yes	3	6	12
no	6	9	9
distance between inner table & insular segment (mm)	37 ± 8†	28 ± 8	26 ± 7
midline shift (mm)	5 ± 5	5 ± 6	6 ± 5

* Data include one patient in whom preoperative angiography was not performed. Significance was determined according to chi-square test or t-test: † = $p < 0.05$, ‡ = $p < 0.01$.

Multivariate Analysis and Outcome Prediction

The results of multivariate analyses for all patients with ICH due to a ruptured MCA aneurysm are listed in Table 6. Variables that were associated with a favorable outcome included age less than 60 years, temporal ICH, a WFNS grade of II or III, absence of a surgical complication, and a hematoma with a volume of 25 ml or less.

TABLE 6
STEPWISE LOGISTIC REGRESSION ANALYSES WITH OUTCOME MEASUREMENT IN PATIENTS WITH ICH DUE TO RUPTURED MIDDLE CEREBRAL ARTERY ANEURYSM*

Variable	Odds Ratio	95% CI	p Value
age (greater than 60 yrs)	1.540	1.014–2.339	0.028
temporal ICH	7.040	0.954–51.932	0.017
WFNS Grade II or III	2.640	0.995–7.005	0.031
surgical complication	0.271	0.103–0.709	0.002
hematoma volume (> 25 ml)	0.587	0.373–0.923	0.016

* CI = confidence interval; ICH = intracerebral hemorrhage; WFNS = World Federation of Neurological Surgeons.

DISCUSSION

Prognostic Factors

Intracerebral hemorrhage is associated with an increased mortality rate in patients with aneurysmal SAH,[1,9] and most neurosurgeons agree that emergency craniotomy with evacuation of the hematoma and aneurysm clipping should be performed.[2-5,7,9,12,13,18,20]. However, few large surgical series of patients with an ICH due to a ruptured MCA aneurysm have been reported. Tapaninaho, et al.,[18] reported a favorable outcome rate of 55% and a mortality rate of 41% in 22 patients with an ICH due to a ruptured MCA aneurysm. In the series of 31 patients reported by Kawamura, et al.,[9] the favorable outcome rate was 81% and mortality was 10%. These studies did not, however, determine which subsets of patients benefited most from surgery. In the present study, we demonstrated that the most important prognostic factor for outcome in patients with ICH due to a ruptured MCA aneurysm is hematoma type and that neurological status at presentation, including brainstem responses, does not correlate with surgical outcome.

Unauthenticated | Downloaded 04/26/23 11:42 AM UTC

Hematoma Type

Pasqualin, et al.,[14] have reported that the incidence rate was 34% in 899 patients with an ICH due to a ruptured aneurysm and that the most frequent site of aneurysm rupture was the MCA (55%). Important factors that predispose to intracerebral aneurysm rupture include the rapid obstruction of the subarachnoid space by blood, fibrin, and fibrous arachnoid and the adhesion of the aneurysmal sac to the pia mater.[5,15] When there is rapid obstruction of the subarachnoid space, aneurysm rupture occurs indirectly into the brain, precipitating SAH. If the aneurysm ruptures at the site where the sac adheres to the pia, it bleeds directly into the brain and no SAH is apparent.

Intracerebral hemorrhages due to a ruptured MCA aneurysm may be located in the external capsule, temporal lobe, and intrasylvian fissure.[5,15] Because a hypertensive ICH usually involves the internal capsule, but SAH due to a ruptured MCA aneurysm does not, the latter is associated with a more favorable outcome. An ICH due to a ruptured MCA aneurysm is fundamentally a subcortical hemorrhage; however, despite emergency craniotomy performed in our study, the favorable outcome rate was only 53% and the mortality rate was 38%. We found these results to be unsatisfactory and so decided to correlate hematoma type with outcome in an effort to improve outcome in our patients.

Patients were divided into three groups: temporal ICH without SAH, intrasylvian hematoma, and ICH with diffuse SAH. Not surprisingly, patients with a temporal ICH without SAH had a favorable outcome following evacuation of the ICH by emergency craniotomy. This group of patients may be most similar to those with an acute epidural hematoma and clearly benefit from early surgical intervention. In contrast, patients with an intrasylvian hematoma or ICH and diffuse SAH have a greater risk for potential complications, including ischemic insult due to vasospasm following surgery, technical difficulties in performing evacuation, and persistently increased intracranial pressure with remaining subarachnoid clots. Evacuation of an intrasylvian hematoma is difficult because there are perforator vessels in the subarachnoid space and fibrous adhesion of the clots. Furthermore, a very careful dissection of the arachnoid membrane is needed in patients with ICH and SAH. In the present study, surgical complications occurred more frequently in patients with ICH and SAH than in the patients with a temporal ICH, and the complication rate correlated significantly with unfavorable outcome. In addition, diffuse SAH was associated with a poorer outcome as compared to the group with intrasylvian hematoma.

Timing of Surgery and Hematoma Volume

In the present study, emergency craniotomy was performed within 24 hours of symptom onset. However, early surgery (within 6 hours of onset) correlated with improved outcome only in patients with an intrasylvian hematoma. Although only four of nine patients with a temporal ICH underwent early surgery, their outcomes were extremely favorable. In patients with a temporal ICH, prognosis is determined by secondary brainstem damage arising from subcortical hemorrhage. Therefore, surgical intervention within 6 hours after symptom onset is not necessary unless the patient exhibits signs of herniation. Because the hematoma clot is not present in the peribrainstem cistern in patients with a temporal ICH, their prognosis is favorable independent of early surgery and/or hematoma volume.

In patients with an intrasylvian hematoma or ICH with diffuse SAH, additional pathological events may occur, such as: 1) primary brain damage due to SAH and ICH; 2) secondary brain damage following SAH (vasospasm); 3) secondary brainstem compression due to the ICH; and 4) direct brainstem compression due to a cisternal clot. The patients with an intrasylvian hematoma usually develop

Unauthenticated | Downloaded 04/26/23 11:42 AM UTC

brainstem compression due to the ICH and peribrainstem clot. Therefore, the prognosis of these patients improves if early surgery (within 6 hours of symptom onset) is performed. However, in patients with ICH and diffuse SAH, early relief of brainstem compression did not alter their prognosis. The most relevant prognostic factor in these patients was a hematoma volume of 25 ml or less.

Recently, the surgical outcomes in moribund patients with ICH who have undergone early craniotomy without angiography have been reported to be relatively favorable.[3,4,12] In this study, only two craniotomies were performed without angiography, and both patients died. We do believe, however, that neurosurgeons should perform early surgery in moribund patients with a temporal ICH, patients with intrasylvian hematoma, and patients with ICH and diffuse ICH who have a hematoma with a volume of 25 ml or less.

Angiographic Diagnosis of Temporal ICH

Our results further emphasize the need to differentiate preoperatively between temporal ICH and an intrasylvian hematoma. It has been previously reported that the anteroposterior projection of cerebral angiograms reveals an increased distance between the insular segment and the internal table in patients with an intrasylvian mass.[11,19] In our study, in patients in whom operative findings indicated a diagnosis of temporal ICH, angiography demonstrated an elevation of the M1 segment and increased distance between the insular segment and internal table. Angiography obtained in patients with an intrasylvian hematoma did not reveal these two findings. We hypothesize that the direction of rupture was usually toward the temporal lobe (lateral or intrasylvian hematoma) in patients with a temporal ICH, whereas in patients with an intrasylvian hematoma, the hematoma may have ruptured into the external capsule after initially forming an intrasylvian hematoma.

CONCLUSIONS

We suggest that indications for surgical intervention in patients with an ICH due to a ruptured MCA aneurysm must be determined in the light of hematoma type. In patients with a temporal ICH, aggressive surgical management is indicated regardless of hematoma volume or neurological status. Similar aggressive surgical intervention within 6 hours of symptom onset is recommended in patients with an intrasylvian hematoma. However, in patients with ICH and diffuse SAH, early intervention appears only to benefit patients whose hematoma volume is 25 ml or less.

References

1. Adams HP Jr, Kassell NF, Torner JC: Usefulness of computed tomography in predicting outcome after aneurysmal subarachnoid hemorrhage: a preliminary report of the Cooperative Aneurysm Study. **Neurology 35:**1263-1267, 1985

2. Bailes JE, Spetzler RF, Hadley MN, et al: Management morbidity and mortality of poor-grade aneurysm patients. **J Neurosurg 72:**559-566, 1990

3. Batjer HH, Samson DS: Emergent aneurysm surgery without cerebral angiography for the comatose patient. **Neurosurgery 28:**283-287, 1991

4. Brandt L, Sonesson B, Ljunggren B, et al: Ruptured middle cerebral artery aneurysm with intracerebral hemorrhage in younger patients appearing moribund: emergency operation? **Neurosurgery 20:**925-929, 1987

Unauthenticated | Downloaded 04/26/23 11:42 AM UTC

5. Crompton MR: Intracerebral haematoma complicating ruptured cerebral berry aneurysm. **J Neurol Neurosurg Psychiatry 25:**378-386, 1962

6. Drake CG: Report of World Federation of Neurological Surgeons Committee on a universal subarachnoid hemorrhage grading scale. **J Neurosurg 68:**985, 1988 (Letter)

7. Heiskanen O, Poranen A, Kuurne T, et al: Acute surgery for intracerebral haematomas caused by rupture of an intracranial arterial aneurysm. A prospective randomized study. **Acta Neurochir 90:**81-83, 1988

8. Jennett B, Bond M: Assessment of outcome after severe brain damage. A practical scale. **Lancet 1:**480-484, 1975

9. Kawamura S, Suzuki A, Sayama I, et al: [Clinical outcome following surgery for intracerebral hematoma associated with ruptured middle cerebral artery aneurysm.] **Neurol Med Chir 28:**1089-1095, 1988 (Jpn)

10. Kawamura S, Suzuki A, Sayama I, et al: [Clinical significance of intracerebral hematomas following aneurysmal rupture.] **Neurol Med Chir 27:**1158-1166, 1987 (Jpn)

11. Krayenbuhl H, Yasargil MG: **Cerebral Angiography, ed 2.** New York: Thieme, 1982, pp 105-136

12. Le Roux PD, Dailey AT, Newell DW, et al: Emergent aneurysm clipping without angiography in the moribund patient with intracerebral hemorrhage: the use of infusion computed tomography scan. **Neurosurgery 33:**189-197, 1993

13. Papo I, Bodosi M, Dozi T: Intracerebral hematomas from aneurysm rupture: Their clinical significance. **Acta Neurochir 89:**100-105, 1987

14. Pasqualin A, Bazzan A, Cavazzani P, et al: Intracranial hematomas following aneurysmal rupture: experience with 309 cases. **Surg Neurol 25:**6-17, 1986

15. Robertson EG: Cerebral lesions due to intracranial aneurysms. **Brain 72:**150-185, 1949

16. Shimoda M: Complications of hypervolemic therapy. **J Neurosurg 79:**799-801, 1993 (Letter)

17. Shimoda M, Oda S, Tsugane R, et al: Intracranial complications of hypervolemic therapy in patients with a delayed ischemic deficit attributed to vasospasm. **J Neurosurg 78:**423- 429, 1993

18. Tapaninaho A, Hernesniemi J, Vapalahti M: Emergency treatment of cerebral aneurysms with large haematomas. **Acta Neurochir 91:**21-24, 1988

19. Taveras JM, Wood EH: **Diagnostic Neuroradiology, ed 2.** Baltimore: Williams & Wilkins, 1976, Vol II, p 716

20. Wheelock B, Weir B, Watts R, et al: Timing of surgery for intracerebral hematomas due to aneurysm rupture. **J Neurosurg 58:**476-481, 1983

Manuscript received August 15, 1996.

Accepted in final form September 16, 1996.

Unauthenticated | Downloaded 04/26/23 11:42 AM UTC

Address reprint requests to: Masami Shimoda, M.D., Department of Neurosurgery, Tokai University School of Medicine, Bohseidai, Isehara, Kanagawa 259-11, Japan.

Click here to view Editorial Perspective on Article 3.

Unauthenticated | Downloaded 04/26/23 11:42 AM UTC