

## The semisitting position: analysis of the risks and surgical outcomes in a contemporary series of 425 adult patients undergoing cranial surgery

\*Andrea Saladino, MD,<sup>1</sup> Massimo Lamperti, MD,<sup>2,4</sup> Antonella Mangraviti, MD,<sup>1,6</sup> Federico G. Legnani, MD,<sup>1</sup> Francesco U. Prada, MD,<sup>1</sup> Cecilia Casali, MD,<sup>1</sup> Luigi Caputi, MD,<sup>3</sup> Paola Borrelli, PhD,<sup>5</sup> and Francesco DiMeco, MD<sup>1,6</sup>

<sup>1</sup>Department of Neurosurgery, <sup>2</sup>Neuro-Intensive Care Unit, <sup>3</sup>Department of Neurology, Cerebrovascular Diseases Unit, Fondazione IRCCS Istituto Neurologico C. Besta, Milan, Italy; <sup>4</sup>Anesthesiology Institute, Cleveland Clinic Abu Dhabi, United Arab Emirates; <sup>5</sup>Department of Public Health, Experimental and Forensic Medicine, Unit of Biostatistics and Clinical Epidemiology, University of Pavia, Italy; and <sup>6</sup>Department of Neurological Surgery, Johns Hopkins Medical School, Baltimore, Maryland

**OBJECTIVE** The objective of this study was to analyze the incidence of the primary complications related to positioning or surgery and their impact on neurological outcome in a consecutive series of patients undergoing elective surgery in the semisitting position.

**METHODS** The authors prospectively collected and retrospectively analyzed data from adult patients undergoing elective surgery in the semisitting position for a cranial disease. Patients were managed perioperatively according to a standard institutional protocol, a standardized stepwise positioning, and surgical maneuvers to decrease the risk of venous air embolism (VAE) and other complications. Intraoperative and postoperative complications were recorded. Neurointensive care unit (NICU) length of stay (LOS) and hospital LOS were the intermediate endpoints. Neurological outcome was the primary endpoint as determined by the modified Rankin scale (mRS) score at 6 months after surgery.

**RESULTS** Four hundred twenty-five patients were included in the analysis. VAE occurred in 90 cases (21%) and it made no significant statistical difference in NICU LOS, hospital LOS, and neurological outcome. No complication was directly related to the semisitting position, although 46 patients (11%) experienced at least 1 surgery-related complication and NICU LOS and hospital LOS were significantly prolonged in this group. Neurological outcome was significantly worse for patients with complications ( $p < 0.0001$ ).

**CONCLUSIONS** Even in the presence of intraoperative VAE, the semisitting position was not related to an increased risk of postoperative deficits and can represent a safe additional option for the benefit of specific surgical and patient needs.

<https://thejns.org/doi/abs/10.3171/2016.8.JNS16719>

**KEY WORDS** semisitting position; venous air embolism; posterior fossa lesion; surgical complications; outcome; diagnostic technique; skull base

THE use of the semisitting position remains a controversial issue whenever neurosurgery is to be performed in the posterior fossa and the cervical region. There are several obvious surgical advantages of using the semisitting rather than the prone or lateral position. These advantages include an easier anatomical orientation, cerebral venous decompression, and CSF drainage, which facilitate cerebellar retraction and allow a better surgical exposure of deep areas such as the pineal region<sup>22</sup>

and the petroclival junction. Furthermore, the gravity-aided blood and irrigation drainage out of the surgical field allows a cleaner dissection and reduces the need for bipolar coagulation.<sup>2,34</sup> The main reported anesthetic advantages of the semisitting position are: 1) better access to the patient's face to assess that airways are safe and the endotracheal tube is always in place; 2) better access for monitoring cranial nerves; and 3) in case of cardiac arrest, performing chest compression is easier.<sup>3,16</sup> Over the past

**ABBREVIATIONS** ASA = American Society of Anesthesiologists; BMI = body mass index; IQR = interquartile range; LOS = length of stay; NICU = neurointensive care unit; mRS = modified Rankin Scale; PACU = postanesthesia care unit; PFO = patent foramen ovale; VAE = venous air embolism.

**SUBMITTED** March 21, 2016. **ACCEPTED** August 11, 2016.

**INCLUDE WHEN CITING** Published online December 16, 2016; DOI: 10.3171/2016.8.JNS16719.

\* Drs. Saladino and Lamperti contributed equally to this work.

decades, 2 major reported complications have discouraged the routine use of the semisitting position in neurosurgery: 1) venous air embolism (VAE) with possible paradoxical air embolism, and 2) intraoperative hypotension. Other major complications, such as symptomatic pneumocephalus, acute subdural hematoma, peripheral nerve injury, laryngeal or lingual edema, and quadriplegia, were also occasionally described.<sup>4,6,8,31,34</sup>

In cases of surgical approaches to the posterior fossa, the occipital region, or other deep brain areas, fear of VAE occurrence and its dramatic consequences has been the main cause of this decline in use of the semisitting position. As a result, the semisitting position has been progressively abandoned in many centers and both neurosurgical and anesthetic trainees were neither adequately exposed to nor trained for its use.<sup>12,25</sup> This created an unbalanced perception of the benefits of the horizontal position,<sup>13,16,36</sup> justified by the absence of convincing evidence in support of nonhorizontal positions for certain neurosurgical procedures.<sup>7,13,30,40</sup>

This work describes the experience of a high-volume tertiary institution in which the semisitting position is routinely used to approach the posterior fossa, paramedian parietooccipital region, and other deep brain areas. Specifically, we sought to assess whether patients undergoing elective cranial neurosurgical procedures in the semisitting position are exposed to an increased risk of major complications directly related to the position, and particularly whether intraoperative anesthetic complications related to the sitting position affect their short- or long-term surgical outcome.

## Methods

### Patient Population and Outcome Measures

The study was approved by the Ethical Committee of the IRCCS Fondazione Istituto Neurologico Besta. The requirement for written informed consent from all patients was waived by the IRB according to national policies for observational studies.

From January 2009 to December 2011, the demographic, clinical, radiological, and surgical information of all adult patients who were admitted to our neurosurgical center (which performs more than 1500 elective craniotomies per year) and who underwent elective surgery in the semisitting position for a cranial disease were prospectively recorded. The anesthesia records were reviewed for evidence of VAE. VAE was considered positive if there was evident aspiration of air from the central venous line catheter and 1 or more of the following diagnostic criteria: 1) any change in sound of the beat-to-beat transthoracic Doppler; 2) fall in end-tidal CO<sub>2</sub> greater than 0.4 kPa; 3) reduction of systolic blood pressure and heart rate greater than 20% compared with the baseline value; and 4) sudden fall in pulse oximetry lower than 94%.<sup>19</sup>

The postoperative clinical data were collected starting from the postanesthesia care unit (PACU) records, including the immediate postanesthesia conditions evaluated with the Aldrete-Kroulik scale,<sup>1</sup> any occurrence of prolonged sedation and/or mechanical ventilation caused by perioperative complications (VAE or hypotensive events),

and neurological postoperative changes. In cases of new or worsened postoperative neurological deficits, the medical records, including operative reports and postoperative imaging, were independently analyzed by a neurosurgeon (A.S.) and an anesthesiologist (M.L.) to identify the surgical complication and define whether it was related to the semisitting position or not.

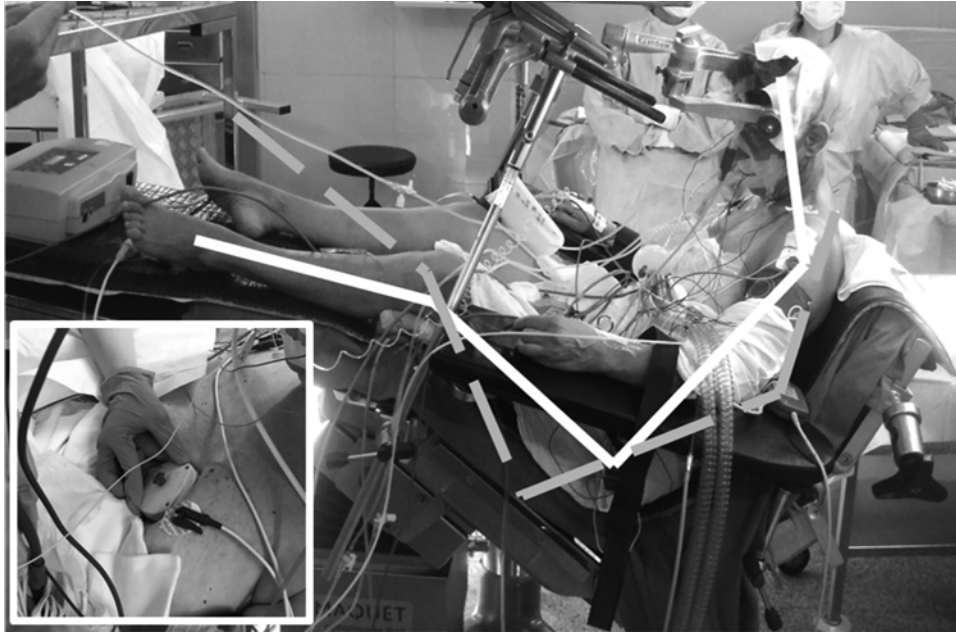
We calculated the overall occurrence of VAE and other complications directly related to the semisitting position (i.e., tension pneumocephalus, supratentorial subdural hematoma, peripheral nerve palsies, and quadriplegia from brainstem compression or hypotensive ischemia), their correlation with patients' preoperative clinical features (including age, sex, body mass index [BMI], American Society of Anesthesiologists [ASA] physical status, and diagnosis), and their impact on postoperative short-term and long-term outcome. Similarly, we calculated the occurrence of surgical complications not related to the semisitting position itself, but to the nature and location of the disease (i.e., hydrocephalus, hematoma caused by surgical manipulation, and focal parenchymal ischemia and/or edema), their correlation with patients' preoperative clinical features, and their impact on surgical outcome. Neurointensive care unit (NICU) length of stay (LOS) and overall hospital LOS were our early outcome measures, whereas the long-term outcome measure was the modified Rankin Scale (mRS) score at a minimum of 6 months (0–1 = no or not significant disability; 2–3 = slight to moderate disability; 4 = moderately severe disability; 5 = severe disability; 6 = death).<sup>33,35</sup>

### Preoperative Assessment

All patients underwent a complete physical status examination according to the recommendations of the European Society of Anaesthesiology.<sup>10</sup> All patients scheduled for surgery in the semisitting position were diagnosed preoperatively by contrast-enhanced transcranial Doppler examination to detect the presence of a right-to-left shunt. Large right-to-left shunts due to a patent foramen ovale (PFO) were endovascularly repaired before surgery. A large right-to-left shunt was defined as the presence of a shower-curtain pattern at rest or after Valsalva maneuver.<sup>9,41</sup>

### Perioperative Management

In the induction room, intraoperative positioning was simulated and the physiological range of head and neck flexion and rotation was checked in awake patients, who were asked to report any possible evoked symptom, such as paresthesia or numbness of the trunk and/or limbs. Induction of general anesthesia was achieved by 1.5 mg/kg of propofol, and 0.15 mg/kg of cisatracurium was used as the main muscle relaxant. An infusion of remifentanyl was started and adjusted accordingly after loss of consciousness to achieve full control of noxious stimulation. Routine monitoring included 5-lead electrocardiography, pulse oximetry, and noninvasive blood pressure measurement every 5 minutes, while intravenous intake and urine output were measured hourly. Bispectral index monitoring was always used and its values were maintained between



**FIG. 1.** Intraoperative positioning. *Noninterrupted lines* define the relationships between the head, neck, trunk, and inferior limbs during the central time of the operation. *Interrupted lines* show the steep Trendelenburg position used from skin incision to dura mater opening. **Inset:** Transthoracic Doppler positioning.

40 and 55. Mechanical ventilation was applied without positive end-expiratory pressure and adjusted to maintain mild hypocapnia. End-tidal  $\text{CO}_2$  was used in conjunction with other parameters to detect VAE and any drop of end-tidal  $\text{CO}_2$  below 20% of the basal value was considered significant for VAE.

After induction of anesthesia, a Bunegin-Albin multi-orifice central venous catheter was placed in the internal jugular vein under ultrasound guidance, and the catheter tip was positioned at the atriocaval junction to aspirate air bubbles in case of VAE.<sup>20</sup> An arterial line was inserted in all patients to assess hemodynamic monitoring, and arterial blood pressure was zeroed at the ear level. In ASA Class 3 patients with a previous history of cardiac dysfunction, a Vigileo FloTrac monitor (Edwards Lifesciences) was used for continuous cardiac output and stroke volume monitoring. In patients with possible postoperative lower cranial nerve dysfunction, a nasogastric tube was inserted to prevent aspiration pneumonia.

### The Semisitting Positioning

Patients were then transferred to the operating table (Maquet), properly covered in advance with flat, large, silicone pads. The semisitting position was achieved in a stepwise manner and every step was double-checked by both the surgeon and the anesthetist, who are equally responsible for the positioning. Usually a senior and a junior neurosurgeon were present during the positioning for education and training purposes. First, the table was gradually and alternatively bent and tilted to obtain a trunk-to-inferior-limbs right angle and a  $30^\circ$  knee flexion, to avoid peripheral nerve or tendon injuries to the lower limbs. Thick silicone pads were usually added under the knees and heels as additional safety measures. When the correct

position of the body was achieved, the flat silicone pad under the trunk was stretched and flattened to avoid any skin fold of the back. Before fixing the head, the upper platform of the table was manually unblocked and bent to  $20^\circ$ – $30^\circ$  to diminish the need for head flexion. The arms were then positioned along the body or on armrests and elevated until there was no tension of the skin and muscles of the neck and shoulders. The Mayfield head holder was then fixed and the head positioned as planned, respecting the physiological range of movements previously checked. In every case, a 3–4 cm space between the chin and the sternum was maintained to guarantee a normal neck venous outflow. For lateral approaches, the head could be rotated up to  $45^\circ$  to the side of the approach and slightly tilted to the opposite side to widen the angle between the shoulder and the mastoid tip (Fig. 1). At this point, all neurological and anesthesiological monitoring was positioned. Intraoperative electrophysiological monitoring was not used to monitor changes during the positioning in all cases, but only if needed because of the direct involvement of the cranial nerves and/or the brainstem by the disease. Fluids were infused to achieve a mean arterial pressure higher than 65 mm Hg or, in the case of patients at high cardiac risk, a stroke volume  $> 60$  ml per beat. Anesthesiologists followed a liberal strategy of crystalloid infusion. As per the institutional protocol at IRCCS Fondazione Istituto Neurologico Besta, a transthoracic Doppler probe was placed between the third and fourth intercostal space at the left mid-clavicle line to assess beat-to-beat sound changes, possibly indicating the occurrence of VAE (Fig. 1, inset). Audible sound changes were verified before starting the surgical procedure by intravenous injection of a bolus of 10 ml of normal saline mixed with 0.25 ml of air.

At the end of all these procedures, the table was el-

evated and tilted to a steep Trendelenburg position (Fig. 1, dashed lines), which was maintained during the approach until the dura opening, when inadvertent damage to the veins of the neck, muscular layers, or bone can cause significant VAEs. The intracranial positive venous pressure caused by the Trendelenburg position has the double positive effect of opposing air aspiration and helping the surgeon identify the venous laceration if VAE occurs.

### Prevention and Management of Intraoperative Complications

VAEs can occur at any time during the operation, but the most critical phase is from skin incision to dura opening. In this phase of the operation a constant communication between neurosurgeons and anesthesiologists is of utmost importance. As described above, a steep Trendelenburg position increases intracranial venous pressure and lessens the risk of air embolism. During skin flap creation and muscle dissection the use of magnifying surgical loupes can help the surgeon identify collapsed veins and coagulate them before cutting, causing inadvertent VAE. In fact, the negative pressure in these veins is a common source of air embolism, which can remain undetected until there is a change in end-tidal CO<sub>2</sub> or other parameters. When detaching the muscles from the occipital bone, bone wax must be readily available on the surgical field and we usually position it on the skin retractor. When performing a lateral approach, it is important to identify the occipital emissary vein to the sigmoid sinus as soon as possible, because its injury is another common source of VAE. Similarly, when approaching the craniocervical junction, the exposure and injury of the suboccipital venous plexus, the perivertebral venous plexus, and the internal vertebral plexus can cause significant VAE. To prevent or to stop air embolism in this situation we use a combination of absorbable hemostat, wet cottonoids, gentle pressure, and irrigation. The most critical situation is probably the craniotomy, as both the diploic veins and the dural sinuses are not under direct vision. Progressive bone chip removal and/or bone drilling over the sinuses are probably the safest way to expose the dura, particularly in elderly patients, but bone reconstruction at the end of the procedure can be poorly effective.<sup>27</sup> We have developed a technique to perform a craniotomy without bur holes that overcomes the issue of blindly addressing the dural sinuses and allows us at the same time to perform an optimal craniotomy in the posterior fossa, reducing the risk of CSF leak or other related complications.<sup>27</sup> When the bone flap is removed, the borders of the native bone are waxed. Generous intermittent irrigation of the surgical field is another essential measure to prevent air embolism and it is maintained through all the described steps.<sup>37</sup> We recommend performing a jugular compression to identify any possible undetected source of VAE before bringing in the surgical microscope and tilting the patient to a position in which the legs are almost parallel to the floor. The dura mater is opened under microscopic vision and bleedings are controlled with hemoclips to avoid dural retraction. Another jugular compression is performed after dural opening before starting the central part of the operation.

When VAE occurs and its source is not immediately

identifiable or time is required to repair the venous injury, the Trendelenburg position is applied again so that the head level is under or at the same level as the feet. Bilateral jugular compression is performed and maintained to increase venous pressure in the head and counteract air aspiration, then fraction of inspired oxygen of 1.0 and a positive end expiratory pressure are applied to help to identify the source of air. At the same time, crucially, air bubbles are aspirated from the central venous catheter and eliminated, because this appears to be the only management strategy with proven clinical efficacy.<sup>31</sup> Blood pressure is monitored, and in case of a sudden drop, fluid administration is increased.

As previously described,<sup>31</sup> for the duration of surgery we prioritized prevention strategies (such as hydration and correct positioning) as well as early recognition of VAE signs and the use of all available tools (e.g., fluids and positive inotropic agents) to manage the VAE event as promptly as possible. This was facilitated by the close collaboration and constant communication between a specialized team of trained anesthesiologists and neurosurgeons.

### Postoperative Management

Extubation was achieved according to the preoperative conditions of the patient, the intraoperative course, the preoperative diagnosis, and the predictable postoperative neurological deficits. After surgery, patients were transferred to the PACU and gradual awakening and extubation was performed. Patients were then monitored for signs of neurological changes before transfer to the NICU. In cases of prolonged operations and/or planned overnight sedation, patients were transferred directly to the NICU. Postoperative hypertension was carefully managed to avoid bleeding complications, particularly in patients affected by vascular malformations, who were kept sedated and ventilated overnight. Similarly, long operations for large tumors or tumors involving the lower cranial nerves or their nuclei in the floor of the fourth ventricle warranted postoperative ventilation. Intracranial pressure monitoring was not routinely used. All patients underwent a postoperative CT scan in the 24 hours after surgery as per institutional protocol. Usually, a CT scan was performed the day after surgery, unless the patient was kept intubated and sedated. In those cases, CT was performed before transfer to the NICU.

### Statistical Analysis

The sample is described with the usual descriptive statistics: mean, standard deviation, median, interquartile range (IQR), and range for continuous variables and proportions for categorical ones. Normality distribution of the variables was assessed using a Shapiro-Wilk test. To evaluate the associations between VAE, surgery-related complications, and patient characteristics (demographic and medical features), the Student t-test was used for continuous variables, and the chi-square or Fisher's exact tests were used for categorical variables. The corresponding nonparametric tests were also used when appropriate. Statistical significance was considered at the  $p < 0.05$  level.

All analyses were performed using Stata/SE for Windows (version 12, StataCorp.).

## Results

Four hundred twenty-five consecutive adult patients were included. There were 246 females and 179 males, with a mean ( $\pm$  SD) age of  $47 \pm 14$  years (range 18–81 years). Patient diagnoses were infratentorial extraaxial tumors ( $n = 204$ , 48%), cerebellar lesions ( $n = 89$ , 21%), craniocervical junction extraaxial tumors ( $n = 33$ , 8%), brainstem lesions ( $n = 44$ , 10%), pineal region tumors ( $n = 23$ , 5%), extraaxial ( $n = 14$ , 3%) or intraaxial ( $n = 11$ , 2%) supratentorial tumors, complex neurovascular conflicts ( $n = 2$ , 0.5%), and Chiari malformations ( $n = 5$ , 1%). The semisitting position was used for microvascular decompression only in the case of multiple cranial nerve involvement. Similarly, this positioning was used for craniocervical junction posterior decompression in Chiari malformations in patients not suitable for the prone position.

### Occurrence of VAE

VAEs occurred in 90 patients (21%). The most common timing of VAE was from skin incision to the end of dural opening ( $n = 55$ , 61%). VAE occurred during tumor removal in 30 cases (33%) and from dural closure to subcutaneous layer suture in 5 patients (6%). There were no statistically significant differences in demographics and preoperative risk factors (ASA class, BMI, and respiratory or cardiac diseases) between patients who did not have intraoperative VAE (Group A) and those in which VAE occurred (Group B). VAE was not significantly associated with a specific preoperative diagnosis. The mean duration of surgery was  $232 \pm 116$  minutes if VAE did not occur and  $217 \pm 112$  minutes if it did occur ( $p = 0.179$ ). The postoperative Aldrete-Kroulik score was greater than 8 in most patients in both groups ( $p = 0.112$ ). Mean and median NICU LOS were  $2 \pm 2$  and 1 day in Group A and  $2 \pm 7$  and 1 day in Group B ( $p = 0.623$ ), respectively. Mean and median hospital LOS were  $9 \pm 8$  and 7 days in Group A and  $11 \pm 14$  and 7 days in Group B ( $p = 0.432$ ), respectively. At 6 months follow-up, the mRS score was  $\leq 1$  in 91% of cases in both groups ( $p = 0.297$ ).

### Surgery-Related Complications

Three hundred seventy-nine patients (89%) did not experience any surgery-related complication (Group C), whereas 46 patients (11%) experienced at least 1 postoperative surgical complication (Group D). Thirty-one patients (7%) developed hydrocephalus and underwent transient or permanent ventricular shunt placement; 22 patients (5%) had a hematoma in or around the surgical cavity, and 7 (2%) required hematoma evacuation. Parenchymal ischemia subsequent to vascular injury during surgery occurred in 12 patients (3%). Cerebral edema around the surgical field was associated with other complications in 12 patients (3%), whereas isolated significant cerebral edema occurred in only 3 patients who underwent an open biopsy for an intraaxial tumor of the brainstem. Three patients with major complications (1 subarachnoid hemorrhage from a previously coiled middle cerebral artery aneu-

rysm) died 4, 5, and 7 days after surgery without leaving the NICU. There were no surgical complications directly related to the semisitting position, such as acute subdural hematoma secondary to tension pneumocephalus, peripheral nerve damage, or quadriplegia due to brainstem or spinal cord hypotensive ischemia or mechanical compression.

Regarding demographics and preoperative risk factors, there was no significant association between patients with no surgical complications (Group C) and patients who experienced a complication (Group D). There was no statistically significant correlation between the occurrence of a surgical complication and the preoperative diagnosis. Surgical complications were not significantly related to VAE ( $p = 0.777$ , Pearson's chi-square test), as they occurred in 10% of patients who had intraoperative VAEs (9/90) and 11% of patients who did not have intraoperative VAEs (37/335).

The mean operative duration was  $227 \pm 112$  minutes and  $245 \pm 136$  minutes in Groups C and D, respectively. The mean postoperative Aldrete-Kroulik score was comparable in the 2 groups ( $p = 0.092$ ). NICU and overall hospital LOS were significantly affected by surgical complications ( $p < 0.0001$ ). Mean and median NICU LOS were  $2 \pm 2$  and 1 days in group C and  $4 \pm 10$  and 2 days in Group D. Overall mean and median hospital LOS were also significantly affected by surgical complications:  $8 \pm 4$  and 7 days in Group C and  $24 \pm 22$  and 16 days in Group D, respectively. At last follow-up, 65% ( $n = 30$ ) of patients with a surgical complication (Group D) had a mRS score  $\leq 1$ , 15% ( $n = 7$ ) had an mRS score of 2 or 3, 13% ( $n = 6$ ) had a score of 4 and the remnant were bedridden or dead ( $n = 3$ ). These outcome scores were significantly different in patients with complications compared with those without complications, as the patients in Group C had an mRS score  $\leq 1$  in 94% ( $n = 356$ ) of cases ( $p < 0.0001$ ). Demographics, clinical features, and all results are summarized in Table 1.

## Discussion

The sitting and semisitting positions have been widely used in neurosurgery since the early 1930s<sup>11,18</sup> and excellent surgical results for patients who underwent operations in these positions have been reported.<sup>15,29,36,38,42</sup> In fact, the semisitting position has several advantages over the prone or supine position: a clear anatomical orientation, improved visualization of deep areas due to decreased venous pressure, increased CSF and blood drainage and gravity-aided cerebellar retraction, and a cleaner surgical field, lessening the need for bipolar coagulation and subsequent loss of a defined interface between the tumor and the surrounding structures, mainly in extraaxial tumors.<sup>2,29</sup> From an anesthetic standpoint, the semisitting position provides immediate access to the trunk and airways in case of respiratory or cardiac complications.

Nonetheless, the fear of rare but possible serious complications, including VAE, paradoxical air embolism, hypotension, and tension pneumocephalus,<sup>4,6,8,26,31,34</sup> caused a progressive decline in the use of the semisitting position in the last 30 years and many trainees in neurosurgery and

TABLE 1. Overview of clinical features and results

Characteristics	All Patients	VAE (%)		p Value	Surgical Complications (%)		p Value
		No, Group A	Yes, Group B		No, Group C	Yes, Group D	
No. of patients	425	335 (79)	90 (21)		379 (89)	46 (11)	
Sex							
Female	246 (58)	189 (56)	57 (63)	0.238	217 (57)	29 (63)	0.453
Male	179 (42)	146 (44)	33 (37)		162 (43)	17 (37)	
Mean age in yrs $\pm$ SD	47 $\pm$ 14	48 $\pm$ 14	44 $\pm$ 15	<b>0.037</b>	47 $\pm$ 15	47 $\pm$ 14	0.922
ASA Class							
1	241 (57)	185 (55)	56 (62)	0.234	212 (56)	29 (63)	0.358
$\geq 2$	184 (43)	150 (45)	34 (38)		167 (44)	17 (37)	
Mean BMI $\pm$ SD	25 $\pm$ 5	25 $\pm$ 5	25 $\pm$ 6	0.508	25 $\pm$ 6	24 $\pm$ 4	0.568
Respiratory disease							
No	393 (92)	309 (92)	84 (93)	0.727	349 (92)	44 (96)	0.386
Yes	32 (8)	26 (8)	6 (7)		30 (8)	2 (4)	
Heart disease							
No	419 (99)	329 (98)	90 (100)	0.201	373 (98)	46 (100)	0.201
Yes	6 (1)	6 (2)	0		6 (2)	0	
Diagnosis							
Infratentorial extraaxial tumors	204 (48)	160 (48)	44 (49)	0.958	182 (48)	22 (48)	0.678
Cerebellar lesions	89 (21)	73 (22)	16 (18)		80 (21)	9 (20)	
Craniocervical junction extraaxial tumors	33 (8)	25 (7)	8 (9)		31 (8)	2 (4)	
Brainstem or high cervical spinal cord lesions	44 (10)	32 (9.6)	12 (13)		37 (10)	7 (15)	
Pineal region tumors	23 (5)	19 (6)	4 (4)		19 (5)	4 (9)	
Supratentorial extraaxial tumor	14 (3)	11 (3)	3 (3)		14 (4)	0	
Supratentorial intraaxial tumor	11 (2)	9 (3)	2 (2)		10 (3)	1 (2)	
Complex neurovascular conflict	2 (0.5)	2 (0.6)	0		2 (0.5)	0	
Chiari malformation	5 (1)	4 (1)	1 (1)		4 (1.1)	1 (2)	
Surgery time (mins)				0.179			0.773
Mean $\pm$ SD	230 $\pm$ 115	232 $\pm$ 116	217 $\pm$ 112		227 $\pm$ 112	245 $\pm$ 136	
Range	50–870						
Aldrete-Kroulik score							
>8	319 (75)	259 (77)	60 (67)	0.112	291 (77)	28 (61)	0.092
$\leq 8$	12 (3)	9 (3)	3 (3)		9 (2)	3 (6)	
Not evaluated	94 (22)	67 (20)	27 (30)		79 (21)	15 (33)	
NICU LOS (days)							
Mean $\pm$ SD	2 $\pm$ 4	2 $\pm$ 2	2 $\pm$ 7	0.623	2 $\pm$ 2	4 $\pm$ 10	<b>&lt;0.0001</b>
Range	1–66						
Median (IQR)	1 (1–1)	1 (1–1)	1 (2–1)		1 (1–1)	2 (4–1)	
Hospital LOS (days)				0.432			<b>&lt;0.0001</b>
Mean $\pm$ SD	10 $\pm$ 9	9 $\pm$ 8	11 $\pm$ 14		8 $\pm$ 4	24 $\pm$ 22	
Range	4–117						
Median (IQR)	7 (9–6)	7 (9–6)	7 (9–6)		7 (8–6)	16 (28–11)	
mRS score at last follow-up							
0–1	386 (91)	304 (91)	82 (91)	0.297	356 (94)	30 (65)	<b>&lt;0.0001</b>
2–3	27 (6)	24 (7.2)	3 (3.3)		20 (5)	7 (15)	
4	8 (2)	5 (1)	3 (3.3)		2 (0.5)	6 (13)	
5	2 (0.5)	1 (0.3)	1 (1.1)		1 (0.3)	1 (2.2)	
6	2 (0.5)	1 (0.3)	1 (1.1)		0 (0)	2 (4.3)	

Boldface type indicates statistical significance.

TABLE 2. Studies of the sitting or semisitting position during surgery

Authors & Year	Study Design	Duration (yrs)	Cases	Cranial (%)	Spinal (%)	Mean Age (yrs)	VAE (%)	ICU Hospital Stay (days)	Impact on Outcome
Standefer et al., 1984	Retro	5	488	51	49	72% in 4th to 6th decade	Overall 6% (7% craniotomies)	NR	3% tension pneumocephalus, 2.3% other complications related to sitting position
Matjasko et al., 1985	Retro & pro	13 (10 retro + 3 pro)	554	45	55	69% in 4th to 6th decade	Overall 23.5 (38% craniotomies, 11% spinal)	NR	Morbidity 1%, mortality 0.9% (all before 1976), 1.8% intraop position change needed
Black et al., 1988	Retro comparative	4	333	100	—	42	45	NR	Better surgical outcome than horizontal positions
Papadopoulos et al., 1994	Pro	NR	53	32	68	49	76 craniotomies, 25 spinal	NR	NR
Stendel et al., 2000	Retro	NR	92	55.4	44.6	51	56.5	NR	None
Bithal et al., 2004	Retro	5	334	100	—	34	28	NR	1 death
Leslie et al., 2006	Retro	7	100	34	66	53	15 craniotomies, 6 spinal	NR	None
Rath et al., 2007	Retro comparative	2	46	100	—	28	15	Less in sitting position	Better surgical outcome than horizontal positions
Jadik et al., 2009	Retro	6	187	100	—	51	1.9	NR	1 tension pneumocephalus
Lindroos et al., 2010	Retro	11	72	100	—	33	19	93% extubated <24 hrs	None
Ganslandt et al., 2013	Retro	16	600	80	20	58	Overall 19 (22 craniotomies)	5 (1–74)	None (3 surgeries stopped, 0.5%)
Ammirati et al., 2013	Retro	4.2	41	100	—	NR	Overall 4.9 (end-tidal CO <sub>2</sub> 26.8, drop in systolic BP 56.1)	NR	None
Hervías et al., 2014	Pro	5	136	68	32	51	Overall 16.2 (21.5 craniotomies, 4.7 spinal)	4 late extubations	5 tension pneumocephalus
Feigl et al., 2014	Pro	2	52 w/ PFO	100	—	42.6	55.7	NR	None

BP = blood pressure; ICU = intensive care unit; NR = not reported; Pro = prospective; Retro = retrospective.

anesthesiology have never been exposed to its advantages and therefore will not use it in the future.<sup>12,25</sup>

Several retrospective series confirmed the safety of the semisitting position, but most of them are old<sup>40</sup> or collected patients who underwent operations over a long period of time by different teams,<sup>30</sup> or included a high percentage of cervical surgeries or pediatric cases.<sup>17,21,28</sup> Most previous studies were also limited by an overestimation of VAE occurrence due to transthoracic echocardiography–restricted diagnosis.<sup>32,39</sup> Although there are no strict criteria for VAE diagnosis during the semisitting position, VAE diagnosis without simultaneous recognition of an attendant pulmonary or systemic event has been shown to induce an overestimation of its occurrence in patients who are otherwise diagnosed with no other surgical or clinical complications.<sup>23</sup> A recent study in which VAE occurrence was associated with its clinical signals showed a very low incidence of VAE (1.6%) in patients who underwent intracra-

nial surgical procedures,<sup>24</sup> whereas another recent study reported a very high incidence of various rates of VAE, but without any clinical sequelae.<sup>14</sup> Therefore, as noted above, evidence of VAE occurrence during surgical procedures in the semisitting position remains highly variable in the literature.<sup>31</sup> Furthermore, the clinical effect of intraoperative VAE on overall neurological outcome is still not clear. Similarly, it is not clear whether the sporadic occurrence of other complications related to the semisitting position is enough to justify the decline in its use and the loss of all the surgical advantages deriving from it,<sup>36</sup> which were demonstrated in retrospective comparative studies on the topic (Table 2).<sup>7,13,30,36,40</sup>

In this study, we hypothesized that the main factor determining neurological outcome was the presence of surgical complications related to the treatment of challenging diseases located in the posterior fossa or other deep areas of the brain, independently from patient positioning. We

prospectively collected and retrospectively analyzed data on a large contemporary series of adult patients operated on in the semisitting position in a short period of time, to analyze the incidence of the primary complications related to the positioning (such as VAE, tension pneumocephalus, peripheral neuropathy, and intraoperative respiratory and hemodynamic distress) or the surgery (such as hydrocephalus, hemorrhage, ischemia secondary to vascular injury, and parenchymal edema) and their effective impact on hospitalization and neurological outcome. All patients included in this study underwent cranial surgery and were managed according to the same institutional protocol to prevent and manage intraoperative and postoperative complications.

### Positioning-Related Complications

VAE occurred in 21% of our cases, which is within the range of previously reported large series and systematic reviews for patients undergoing cranial surgery.<sup>4,13,17,32,40</sup> The use of transthoracic Doppler to detect the occurrence of VAE could have caused more false-positive episodes, but we prefer to increase our threshold of attention to detect even minor episodes of VAE and treat them as soon as they are detected by a change in the sound of cardiac Doppler.<sup>19</sup> The patients' presurgical clinical conditions (i.e., sex, ASA Class, BMI, and pulmonary or cardiac disease) were recorded and analyzed, and no risk factor for intraoperative VAE was identified except for age, with younger patients being at higher risk ( $p = 0.03$ ). A possible explanation for VAE occurrence in our series is that the exposure of dural sinuses during cranial surgery is at high risk of VAE, as dural veins do not collapse and the surgeon can damage them or their emissaries during craniotomy.<sup>40</sup> In our series, 61% of VAEs occurred from skin incision to dural opening. During this phase of the operation, therefore, a constant communication between the surgical and the anesthetic teams is essential to prevent VAE, or promptly find the source of air embolism and counteract its effects on cardiac and respiratory function. In all cases in our series this complication was efficiently managed by the neurosurgical and anesthetic teams with no need to stop the operation. The mean length of operation was not significantly different, whether VAE occurred or not ( $p = 0.179$ ). Similarly, immediate clinical conditions after surgery, as assessed by Aldrete-Kroulik score at extubation ( $p = 0.112$ ), and by NICU ( $p = 0.623$ ) and hospital LOS ( $p = 0.432$ ), were not affected by intraoperative complications related to the semisitting position, as previously reported by other authors.<sup>7,17,36</sup> Neurological outcome at 6-months follow-up was the same in patients who did or did not have intraoperative VAE, with more than 90% of patients in both groups having an mRS score  $\leq 1$ . No other serious complication historically related to the semisitting position, such as tension pneumocephalus,<sup>26</sup> peripheral neuropathy, quadriplegia due to cervical cord ischemia and/or compression,<sup>30</sup> or macroglossia occurred in our series.<sup>34</sup> This finding confirms the utmost importance of a specific training of all the staff involved for a correct and safe positioning, which is obviously facilitated by the routine use of this position. As previously specified, we do not routinely use neuromonitoring solely for patient positioning, because we consider it

over-precautionary if the physiological range of head and neck movement is respected. In fact, quadriplegia or triplegia after procedures performed in the semisitting position is only occasionally reported, with approximately 30 cases noted in the literature.<sup>2,34</sup> Conversely, all patients harboring skull base tumors and brainstem or pineal region tumors/vascular malformations, which constitute more than 70% of cases in our series, underwent operations using neuromonitoring to prevent surgery-related complications.

### Surgery-Related Complications

To confirm our hypothesis regarding the safety of the semisitting position in our group of patients, we then analyzed the impact of complications related to the surgical procedure itself on our endpoints. Eleven percent of our patients experienced at least 1 postoperative surgery-related complication, with hydrocephalus as the most common (7%). It is important to note that we routinely do not treat ventricular dilation when surgery in the semisitting position is planned, as CSF shunting or drainage has been described as a potential risk factor for developing tension pneumocephalus.<sup>5</sup> If needed, we prefer to anticipate the operation rather than treating the hydrocephalus. The second most common complication was hematoma in or around the surgical cavity, which was demonstrated on postoperative scans in 22 patients (5%). Only 7 of these patients required a second surgery for hematoma evacuation. Other complications were parenchymal ischemia subsequent to vascular injury during surgery (3%) and/or cerebral edema around the surgical field (3%). No risk factors for surgical complications were found when analyzing demographics and preoperative clinical conditions. Similarly to previous studies, comparing complications related to posterior fossa surgery in patients operated on in either the sitting position or in the horizontal position,<sup>36</sup> there was no correlation between VAE and surgery-related complications. Preoperative diagnosis and disease location were not associated with a specific surgery-related complication. Curiously, the Aldrete-Kroulik score at extubation was the same in patients who later developed a surgical complication and in those who did not ( $p = 0.092$ ). We hypothesize that this finding may reflect the time required for some complications to establish themselves and become symptomatic. Conversely, as was predictable, NICU LOS ( $p = 0.0001$ ) and hospital LOS ( $p = 0.0001$ ) were markedly prolonged when a surgical complication occurred. Most importantly, neurological outcome at 6 months was significantly worse, with only 65% of patients having an mRS score  $\leq 1$  as compared with 94% of patients in the absence of any surgery-related complication.

### Strengths and Weaknesses of the Study

The main limitation of the present study is that there is no comparison with a similar cohort of patients treated for the same pathologies by the same medical team in the prone or lateral position. Nonetheless, because we did not record any complication directly related to the semisitting position, we believe that such a comparison would have not been significant. Conversely, we analyzed a very homogeneous, large cohort of adult patients undergoing elective cranial surgery, so there is no confounding factor such as

emergencies or spinal or pediatric cases. Furthermore, all patients underwent operations in a short period of time by the same medical and nursing staff, using the same perioperative protocol, so there were no differences dependent upon the timespan between the first and the last patient included. Finally, this is a single-center but not a single-surgeon series, as several surgeons and anesthesiologists, including senior doctors, attending doctors, and trainees, were involved in patient positioning, surgery, and postoperative management. Therefore, in the authors' opinion, the results of the present study could be generalized to all tertiary centers using the same or a similar protocol to prevent and manage complications related to the semisitting position. The routine use of the semisitting position in our hospital and the know-how of the entire team probably had an impact in determining the outcome, but this is hardly quantifiable.

## Conclusions

Surgery for lesions possibly requiring the semisitting position is demanding and dangerous due to the small space and the importance of the neural and vascular structures involved, regardless of the position used to approach them. Our results demonstrate that the semisitting position does not carry any significant additional risk to patients, as long as the neurosurgical and anesthetic teams performing the surgical procedure follow a strict perioperative protocol and are educated on the risks and remedies associated with the position. An appropriate protocol for VAE diagnosis and treatment should be available whenever there is the risk of air embolism related to the position of the patient (semisitting position) or to the site of surgery (above the right heart level).

The combined results of the present and previous studies show that the surgical advantages of the semisitting position are not overcome by its surgical and anesthesiological risks. The semisitting position can be considered a safe alternative to horizontal positions, as long as the team is trained to use it. The operating neurosurgeon should then have the necessary know-how and include the semisitting position among the possible alternatives in his or her armamentarium when managing challenging disease in the posterior fossa or other deep brain areas.

## References

1. Aldrete JA, Kroulik D: A postanesthetic recovery score. *Anesth Analg* 49:924–934, 1970
2. Ammirati M, Lamki TT, Shaw AB, Forde B, Nakano I, Mani M: A streamlined protocol for the use of the semi-sitting position in neurosurgery: a report on 48 consecutive procedures. *J Clin Neurosci* 20:32–34, 2013
3. Beltran SL, Mashour GA: Unsuccessful cardiopulmonary resuscitation during neurosurgery: is the supine position always optimal? *Anesthesiology* 108:163–164, 2008
4. Bithal PK, Pandia MP, Dash HH, Chouhan RS, Mohanty B, Padhy N: Comparative incidence of venous air embolism and associated hypotension in adults and children operated for neurosurgery in the sitting position. *Eur J Anaesthesiol* 21:517–522, 2004
5. Black PM, Davis JM, Kjellberg RN, Davis KR: Tension pneumocephalus of the cranial subdural space: a case report. *Neurosurgery* 5:368–370, 1979
6. Black S, Cucchiara RF, Nishimura RA, Michenfelder JD: Parameters affecting occurrence of paradoxical air embolism. *Anesthesiology* 71:235–241, 1989
7. Black S, Ockert DB, Oliver WC Jr, Cucchiara RF: Outcome following posterior fossa craniectomy in patients in the sitting or horizontal positions. *Anesthesiology* 69:49–56, 1988
8. Buhre W, Weyland A, Buhre K, Kazmaier S, Mursch K, Schmidt M, et al: Effects of the sitting position on the distribution of blood volume in patients undergoing neurosurgical procedures. *Br J Anaesth* 84:354–357, 2000
9. Caputi L, Carriero MR, Falcone C, Parati E, Piotti P, Materazzo C, et al: Transcranial Doppler and transesophageal echocardiography: comparison of both techniques and prospective clinical relevance of transcranial Doppler in patent foramen ovale detection. *J Stroke Cerebrovasc Dis* 18:343–348, 2009
10. De Hert S, Imberger G, Carlisle J, Diemunsch P, Fritsch G, Moppett I, et al: Preoperative evaluation of the adult patient undergoing non-cardiac surgery: guidelines from the European Society of Anaesthesiology. *Eur J Anaesthesiol* 28:684–722, 2011
11. De Martel T: Surgical treatment of cerebral tumours. Technical considerations. *Surg Gynecol Obstet* 52:381–385, 1931
12. Elton RJ, Howell RS: The sitting position in neurosurgical anaesthesia: a survey of British practice in 1991. *Br J Anaesth* 73:247–248, 1994
13. Fathi AR, Eshtehardi P, Meier B: Patent foramen ovale and neurosurgery in sitting position: a systematic review. *Br J Anaesth* 102:588–596, 2009
14. Feigl GC, Decker K, Wurms M, Krischek B, Ritz R, Unertl K, et al: Neurosurgical procedures in the semisitting position: evaluation of the risk of paradoxical venous air embolism in patients with a patent foramen ovale. *World Neurosurg* 81:159–164, 2014
15. Ferroli P, Sinisi M, Franzini A, Giombini S, Solero CL, Broggi G: Brainstem cavernomas: long-term results of microsurgical resection in 52 patients. *Neurosurgery* 56:1203–1214, 2005
16. Gale T, Leslie K: Anaesthesia for neurosurgery in the sitting position. *J Clin Neurosci* 11:693–696, 2004
17. Ganslandt O, Merkel A, Schmitt H, Tzabazis A, Buchfelder M, Eyupoglu I, et al: The sitting position in neurosurgery: indications, complications and results. A single institution experience of 600 cases. *Acta Neurochir (Wien)* 155:1887–1893, 2013
18. Gardner WJ: Intracranial operations in the sitting position. *Ann Surg* 101:138–145, 1935
19. Gracia I, Fabregas N: Craniotomy in sitting position: anesthesiology management. *Curr Opin Anaesthesiol* 27:474–483, 2014
20. Hanna PG, Gravenstein N, Pashayan AG: In vitro comparison of central venous catheters for aspiration of venous air embolism: effect of catheter type, catheter tip position, and cardiac inclination. *J Clin Anesth* 3:290–294, 1991
21. Harrison EA, Mackersie A, McEwan A, Facer E: The sitting position for neurosurgery in children: a review of 16 years' experience. *Br J Anaesth* 88:12–17, 2002
22. Hernesniemi J, Romani R, Albayrak BS, Lehto H, Dashti R, Ramsey C III, et al: Microsurgical management of pineal region lesions: personal experience with 119 patients. *Surg Neurol* 70:576–583, 2008
23. Hervías A, Valero R, Hurtado P, Gracia I, Perelló L, Tercero FJ, et al: [Detection of venous air embolism and patent foramen ovale in neurosurgery patients in sitting position.] *Neurocirugía (Astur)* 25:108–115, 2014 (Span)
24. Jadik S, Wissing H, Friedrich K, Beck J, Seifert V, Raabe A: A standardized protocol for the prevention of clinically relevant venous air embolism during neurosurgical interventions in the semisitting position. *Neurosurgery* 64:533–539, 2009

25. Kida H, Nishikawa N, Matsunami K, Kawahito M, Ota M, Miyao S: [Sitting position in the neurosurgery: the results of a questionnaire sent to neurosurgeons of medical colleges.] **Masui** **49**:566–569, 2000 (Jpn)
26. Kitahata LM, Katz JD: Tension pneumocephalus after posterior-fossa craniotomy, a complication of the sitting position. **Anesthesiology** **44**:448–450, 1976
27. Legnani FG, Saladino A, Casali C, Vetrano IG, Varisco M, Mattei L, et al: Craniotomy vs. craniectomy for posterior fossa tumors: a prospective study to evaluate complications after surgery. **Acta Neurochir (Wien)** **155**:2281–2286, 2013
28. Leslie K, Hui R, Kaye AH: Venous air embolism and the sitting position: a case series. **J Clin Neurosci** **13**:419–422, 2006
29. Lindroos AC, Niiya T, Randell T, Romani R, Hernesniemi J, Niemi T: Sitting position for removal of pineal region lesions: the Helsinki experience. **World Neurosurg** **74**:505–513, 2010
30. Matjasko J, Petrozza P, Cohen M, Steinberg P: Anesthesia and surgery in the seated position: analysis of 554 cases. **Neurosurgery** **17**:695–702, 1985
31. Mirski MA, Lele AV, Fitzsimmons L, Toung TJ: Diagnosis and treatment of vascular air embolism. **Anesthesiology** **106**:164–177, 2007
32. Papadopoulos G, Kuhly P, Brock M, Rudolph KH, Link J, Eyrich K: Venous and paradoxical air embolism in the sitting position. A prospective study with transoesophageal echocardiography. **Acta Neurochir (Wien)** **126**:140–143, 1994
33. Patel N, Rao VA, Heilman-Espinoza ER, Lai R, Quesada RA, Flint AC: Simple and reliable determination of the modified Rankin scale score in neurosurgical and neurological patients: the mRS-9Q. **Neurosurgery** **71**:971–975, 2012
34. Porter JM, Pidgeon C, Cunningham AJ: The sitting position in neurosurgery: a critical appraisal. **Br J Anaesth** **82**:117–128, 1999
35. Rankin J: Cerebral vascular accidents in patients over the age of 60. II. Prognosis. **Scott Med J** **2**:200–215, 1957
36. Rath GP, Bithal PK, Chaturvedi A, Dash HH: Complications related to positioning in posterior fossa craniectomy. **J Clin Neurosci** **14**:520–525, 2007
37. Rozet I, Vavilala MS: Risks and benefits of patient positioning during neurosurgical care. **Anesthesiol Clin** **25**:631–653, 2007
38. Samii M, Matthies C: Management of 1000 vestibular schwannomas (acoustic neuromas): surgical management and results with an emphasis on complications and how to avoid them. **Neurosurgery** **40**:11–23, 1997
39. Schäfer ST, Lindemann J, Brendt P, Kaiser G, Peters J: Intracardiac transvenous echocardiography is superior to both precordial Doppler and transesophageal echocardiography techniques for detecting venous air embolism and catheter-guided air aspiration. **Anesth Analg** **106**:45–54, 2008
40. Standefer M, Bay JW, Trusso R: The sitting position in neurosurgery: a retrospective analysis of 488 cases. **Neurosurgery** **14**:649–658, 1984
41. Stendel R, Gramm HJ, Schröder K, Lober C, Brock M: Transcranial Doppler ultrasonography as a screening technique for detection of a patent foramen ovale before surgery in the sitting position. **Anesthesiology** **93**:971–975, 2000
42. Yaşargil MG, Fox JL: The microsurgical approach to acoustic neurinomas. **Surg Neurol** **2**:393–398, 1974

## Disclosures

The authors report no conflict of interest concerning the materials or methods used in this study or the findings specified in this paper.

## Author Contributions

Conception and design: Saladino, Lamperti, Di Meco. Acquisition of data: Saladino, Lamperti, Mangraviti, Legnani, Prada, Casali, Caputi. Analysis and interpretation of data: Saladino, Lamperti, Mangraviti. Drafting the article: Saladino, Lamperti, Mangraviti, Legnani. Critically revising the article: Legnani, Prada, Caputi, Di Meco. Reviewed submitted version of manuscript: Saladino, Lamperti, Di Meco. Approved the final version of the manuscript on behalf of all authors: Saladino. Statistical analysis: Borrelli. Administrative/technical/material support: Casali. Study supervision: Borrelli, Di Meco.

## Supplemental Information

### Previous Presentations

Portions of this work were presented in abstract form at the CNS Annual Meeting, in San Francisco, California, October 19–23, 2013, and at the 64th Congress of the Italian Society of Neurosurgery (SINch), in Naples, Italy, June 24–26, 2015.

## Correspondence

Andrea Saladino, Department of Neurosurgery, Fondazione IRCCS Istituto Neurologico C. Besta, Via Celoria, 11, Milan 20133, Italy. email: andrea.saladino@gmail.com.