

## Transvenous embolization of conus spinal arteriovenous malformation: illustrative case

Mohammad Anadani, MD, and Jonathan Lena, MD

Department of Neurosurgery, Medical University of South Carolina, Charleston, South Carolina

**BACKGROUND** Spinal arteriovenous malformations (AVMs) are the most challenging spinal vascular malformations. Endovascular transarterial embolization of spinal AVM has been well described. However, transvenous embolization has not been previously reported. In this case report, the authors describe transvenous embolization of a recurrent intramedullary/conus spinal AVM that was previously deemed unamenable to endovascular therapy

**OBSERVATIONS** A 30-year-old female presented with debilitating lumbar back pain and was found to have an intramedullary spinal AVM at the level of the conus medullaris. Initially, the AVM was treated with endovascular arterial embolization and subsequently with microsurgical resection. However, on follow-up angiography, the AVM had recurred. Further arterial embolization was deemed not possible because of anatomical challenges. After careful consideration, endovascular transvenous embolization was performed with successful occlusion of the AVM nidus.

**LESSONS** Transvenous embolization is an alternative route for endovascular treatment of spinal AVMs that have an accessible single draining vein.

<https://thejns.org/doi/abs/10.3171/CASE22382>

**KEYWORDS** arteriovenous malformation; spinal; treatment

Conus medullaris spinal arteriovenous malformations (AVMs) are a rare spinal vascular malformation that can lead to significant morbidity.<sup>1,2</sup> Conus AVMs can present with acute neurological deterioration due to subarachnoid/intramedullary hemorrhage or with stepwise gradual progression due to venous congestion, mechanical compression, or ischemia due to vascular steal.<sup>1,3</sup> Treatment options include endovascular embolization alone, microsurgery, or a combined approach. Endovascular treatment of conus spinal AVMs is challenging due to involvement of multiple eloquent feeders, which commonly originate from the anterior spinal artery. Most of the previous reports of endovascular treatment of spinal AVMs described arterial embolization.<sup>1-5</sup> Herein, we report a case of conus spinal AVM treated via transvenous embolization.

### Illustrative Case

#### Presentation

A 30-year-old female initially presented with debilitating lower thoracic and lumbar pain radiating into her legs as well as bilateral lower extremity numbness. Magnetic resonance imaging (MRI) showed

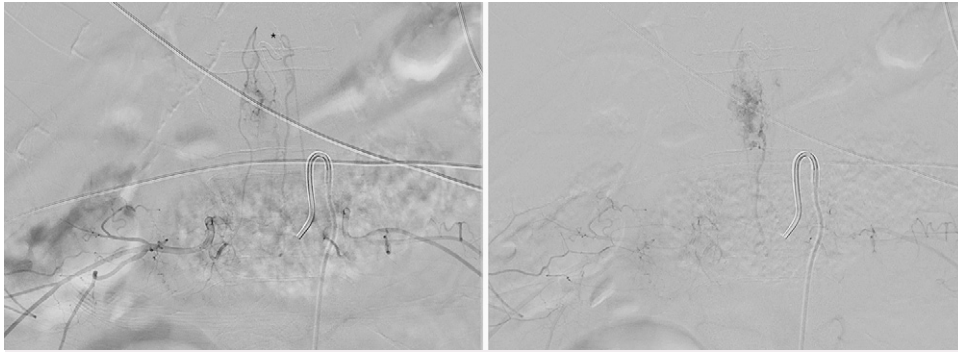
irregular enhancing lesion at the level of T12 vertebral body with associated expansion of the conus medullaris. Subsequent spinal angiogram demonstrated a spinal AVM that was exclusively fed by the right and left T10 segmental arteries. The patient underwent embolization of the left T10 segmental artery branch supplying the AVM using Onyx Liquid Embolic agent (Medtronic). Six-month follow-up spinal angiogram showed faint residual filling of the nidus with no early venous drainage. One-year follow-up spinal angiogram demonstrated continued filling of the spinal AVM with arterial supply from the bilateral L1 segmental arteries. Endovascular embolization was attempted but was unsuccessful due to inability to access the feeding arteries. Attempted microsurgical resection of the spinal AVM was performed; however, the resection was limited secondary to neuro-monitoring changes during the surgery. The patient's symptoms continued to be debilitating and follow-up angiogram 1 year later demonstrated residual filling of the spinal AVM that was fed by feeders from the bilateral L1 segmental arteries and drained into the anterior spinal vein, which, in turn, drained into the lateral sacral vein. After careful consideration and discussion with the patient, we decided to attempt endovascular transvenous embolization of the spinal AVM.

**ABBREVIATIONS** AVM = arteriovenous malformation; MRI = magnetic resonance imaging.

**INCLUDE WHEN CITING** Published January 16, 2023; DOI: 10.3171/CASE22382.

**SUBMITTED** September 12, 2022. **ACCEPTED** October 7, 2022.

© 2023 The authors, CC BY-NC-ND 4.0 (<http://creativecommons.org/licenses/by-nc-nd/4.0/>).

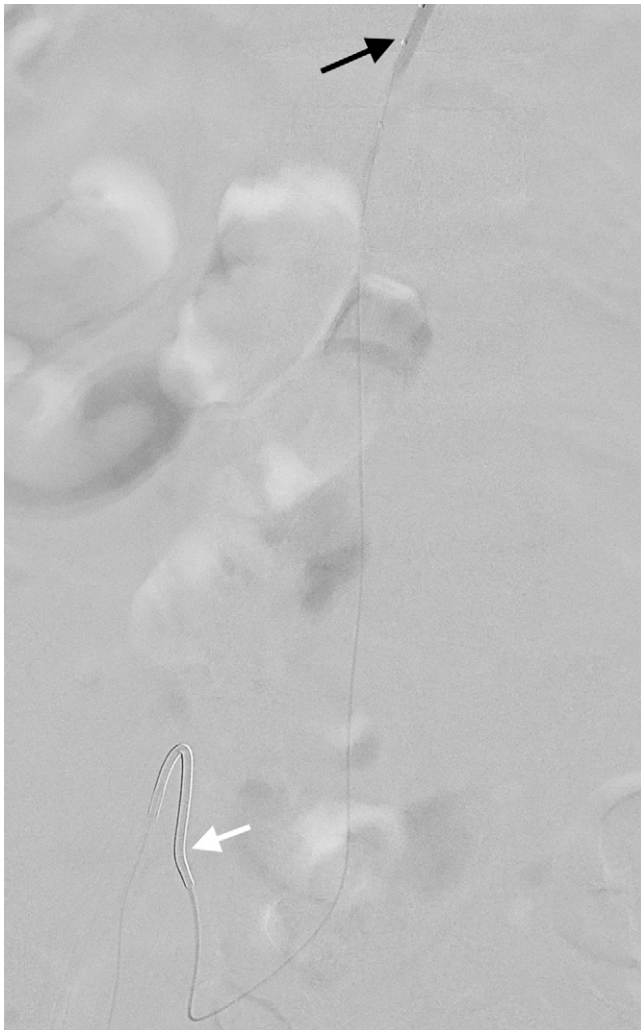


**FIG. 1.** Pre-embolization early (**right**) and late (**left**) anterior-posterior projection arteriograms showing a spinal arteriovenous malformation that is fed by the bilateral L1 segmental arteries. The Onyx cast from the first transarterial embolization procedure is denoted by the asterisk (\*).

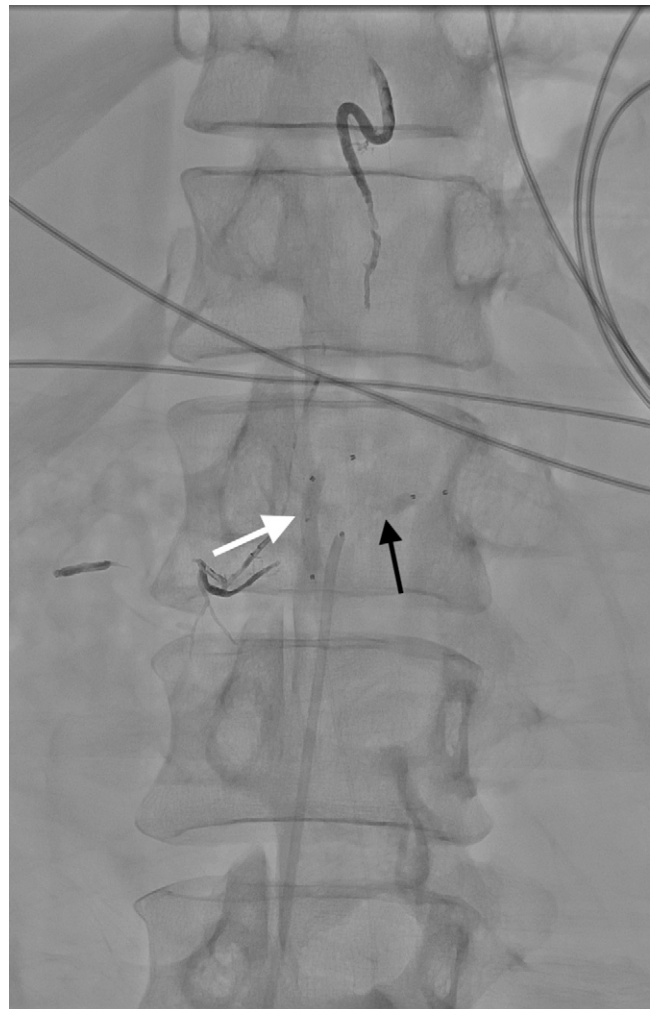
### Endovascular Treatment

The procedure was performed under general anesthesia. A 6-Fr sheath was placed in the right common femoral artery and a second

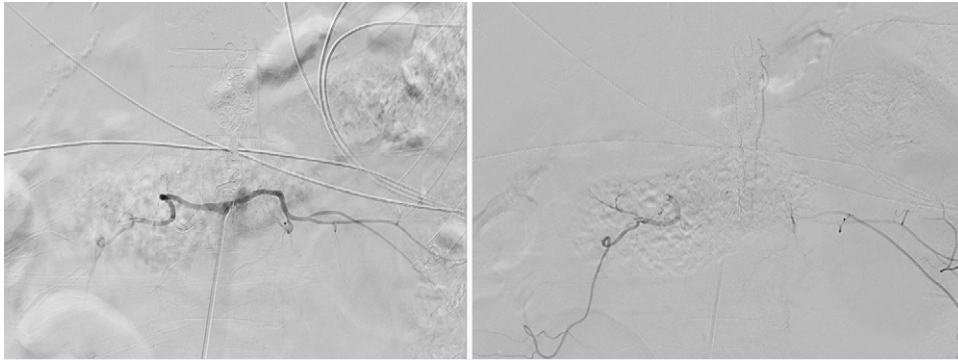
6-Fr sheath was placed in the right common femoral vein. A 5-Fr Mickelson diagnostic catheter (Cook) was used to access the segmental arteries for spinal angiogram. Spinal angiogram again demonstrated



**FIG. 2.** Anterior-posterior projection angiogram showing a Mickelson catheter in the internal iliac vein (*white arrow*) and the dual-lumen balloon catheter in the anterior spinal vein (*black arrow*).



**FIG. 3.** Non-subtracted anterior-posterior projection angiogram showing a balloon inflated in the anterior spinal vein (*white arrow*) and the balloon inflated in the L1 segmental artery (*black arrow*) before venous embolization.



**FIG. 4.** Postembolization early (right) and late (left) arteriograms showing the Onyx cast in the nidus with complete obliteration in the nidus.

recurrence of the previously treated spinal AVM that was mainly fed by branches of the bilateral L1 segmental arteries (Fig. 1). The artery of Adamkiewicz was noted to originate from the left T10 segmental artery. Onyx embolization of the origin of the right L1 segmental artery feeder pedicle branch was performed. Multiple unsuccessful attempts were made to access the left L1 segmental artery spinal branch. The decision was then made to proceed with transvenous embolization. Using a Mickelson diagnostic catheter (Cook) the internal iliac vein was selected (Fig. 2). A Scepter 4 × 10-mm dual lumen balloon catheter (Microvention) was advanced over the microwire to the lateral sacral vein and then to the anterior spinal vein under roadmap guidance (Fig. 2). A second Scepter 4 × 10-mm balloon microcatheter was advanced into the left L1 segmental artery and inflated to achieve flow arrest. The Scepter balloon within the anterior spinal vein was then inflated and transvenous embolization was performed using Onyx liquid embolic agent (Medtronic) (Fig. 3).

### Outcome and Follow-Up

Postembolization spinal angiogram of T9–L3 segmental arteries demonstrated complete obliteration of the AVM with no residual filling (Fig. 4). Post-procedurally, the patient experienced right foot dorsiflexion and plantar flexion paralysis that improved significantly before discharge (Medical Research Council scale 3/5 for both plantar flexion and dorsal flexion). Follow-up thoracic and lumbar spinal MRI demonstrated no evidence of acute infarction or hemorrhage.

## Discussion

### Observations

Our case demonstrated the feasibility of transvenous embolization of spinal AVMs. To our knowledge, this is the first case to describe transvenous embolization of an intramedullary/conus spinal AVM.

Transarterial Onyx embolization of intramedullary and conus AVMs has been shown to be safe. Corkill et al.<sup>4</sup> reported a case series of 17 patients with spinal intramedullary AVM treated with transarterial endovascular embolization. Complete obliteration was achieved in 37.5% of patients and subtotal occlusion was achieved in 31.25%. Wilson et al.<sup>2</sup> reported 16 patients with conus AVMs that were treated with microsurgical resection with presurgical endovascular transarterial embolization in 8 patients. Complete obliteration was noted in 88%.

In recent years, reports of endovascular spinal venous navigation have emerged, expanding our understanding of the spinal venous system and suggesting the feasibility of venous embolization of spinal

vascular lesions.<sup>6,7</sup> Moreover, transvenous embolization of intracranial AVMs has been well described.<sup>8</sup> We used the knowledge gained from previous reports and our experience in intracranial venous embolization in our procedural planning. We chose transvenous embolization in our case because the AVM had a single draining vein and because the arterial pedicles were inaccessible. To lower the risk of reflex, we used flow arrest by inflating a balloon in the arterial pedicle and induced systemic hypotension. We were able to achieve complete obliteration without significant reflex.

### Lessons

Our case supports previous studies that demonstrated the feasibility and safety of endovascular treatment of spinal AVMs and suggests that transvenous embolization is an alternative approach in selected cases.<sup>1,2,4,5</sup> Further studies are needed to evaluate the safety and efficacy of transvenous embolization of spinal AVMs.

## References

1. Ducruet AF, Crowley RW, McDougall CG, Albuquerque FC. Endovascular management of spinal arteriovenous malformations. *J Neurointerv Surg.* 2013;5(6):605–611.
2. Wilson DA, Abla AA, Uschold TD, McDougall CG, Albuquerque FC, Spetzler RF. Multimodality treatment of conus medullaris arteriovenous malformations: 2 decades of experience with combined endovascular and microsurgical treatments. *Neurosurgery.* 2012;71(1):100–108.
3. Lenck S, Nicholson P, Tymianski R, et al. Spinal and paraspinous arteriovenous lesions. *Stroke.* 2019;50(8):2259–2269.
4. Corkill RA, Mitsos AP, Molyneux AJ. Embolization of spinal intramedullary arteriovenous malformations using the liquid embolic agent, Onyx: a single-center experience in a series of 17 patients. *J Neurosurg Spine.* 2007;7(5):478–485.
5. Biondi A, Merland JJ, Reizine D, et al. Embolization with particles in thoracic intramedullary arteriovenous malformations: long-term angiographic and clinical results. *Radiology.* 1990;177(3):651–658.
6. Borg N, Cutsforth-Gregory J, Oushy S, et al. Anatomy of spinal venous drainage for the neurointerventionalist: from puncture site to intervertebral foramen. *AJNR Am J Neuroradiol.* 2022;43(4):517–525.
7. Brinjikji W, Garza I, Whealy M, et al. Clinical and imaging outcomes of cerebrospinal fluid-venous fistula embolization. *J Neurointerv Surg.* 2022;14(10):953–956.
8. Chen CJ, Norat P, Ding D, et al. Transvenous embolization of brain arteriovenous malformations: a review of techniques, indications, and outcomes. *Neurosurg Focus.* 2018;45(1):E13.

**Disclosures**

Dr. Lena reported personal fees from Stryker outside the submitted work. No other disclosures were reported.

**Author Contributions**

Conception and design: both authors. Acquisition of data: Lena. Analysis and interpretation of data: Lena. Drafting of the article:

Anadani. Critically revising the article: Lena. Reviewed submitted version of manuscript: Lena. Approved the final version of the manuscript on behalf of both authors: Lena.

**Correspondence**

Jonathan Lena: Medical University of South Carolina, Charleston, SC. lena@musc.edu.